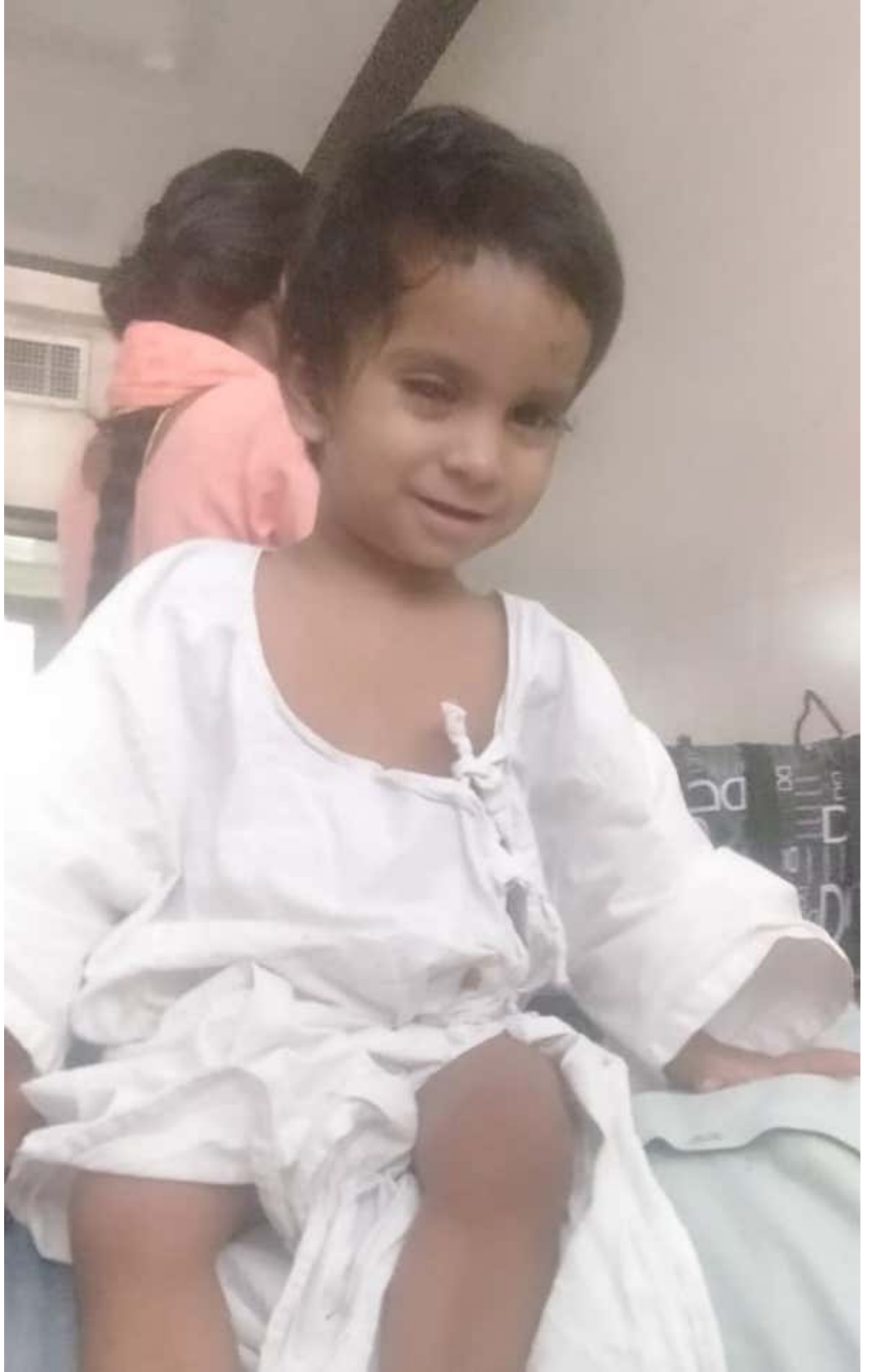
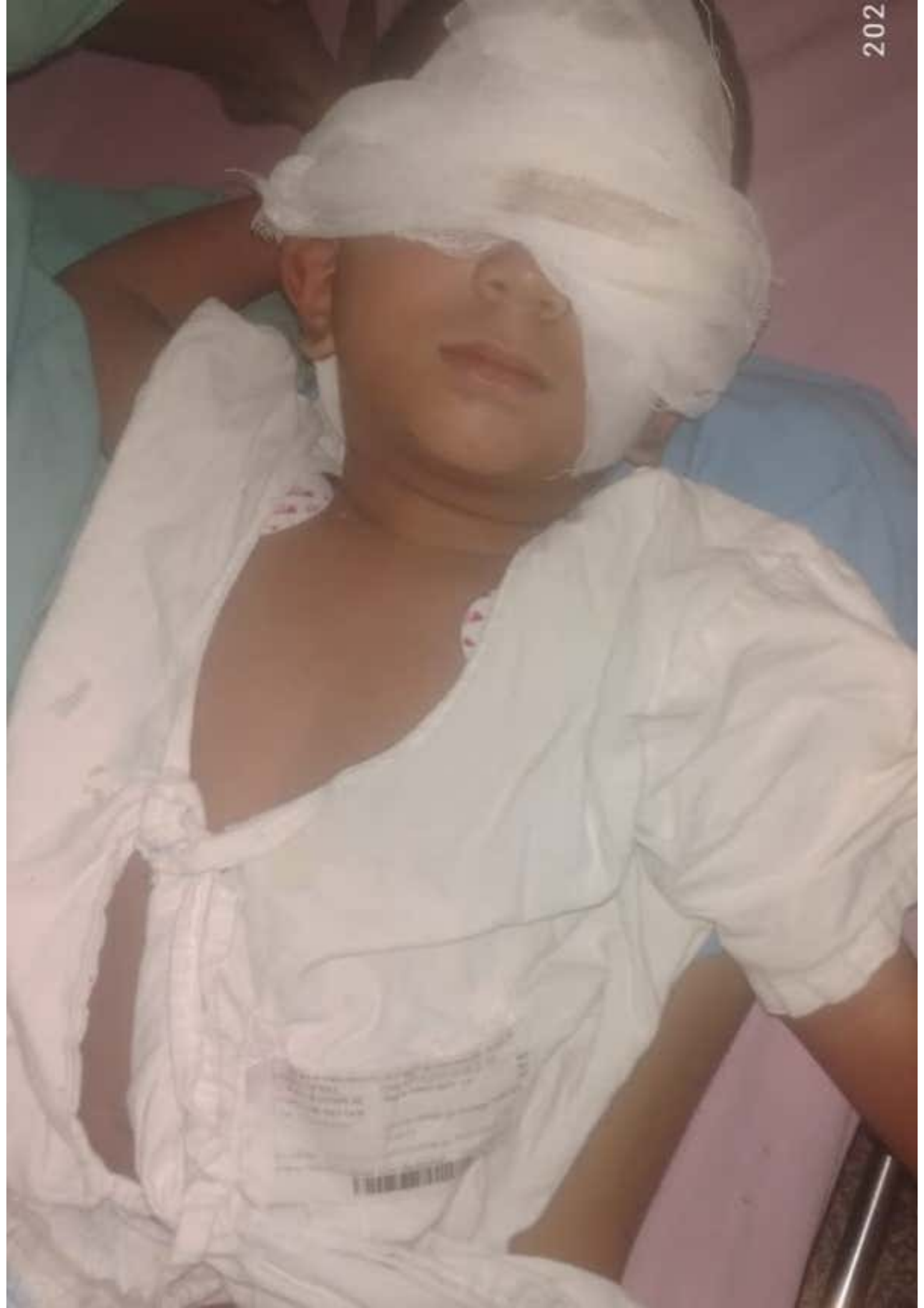




PRE OPERATIVE ORDERS

Signature

- dia, mark (R)
- shift pt. to renal lab labs on call
- NPO
 - 8 hr solids
 - 6 hr liquid
 - 4 hr. water

9/6/25

1 - dia, mark (R) vitals (R) NPO (R)

2 - shift pt. to OT on call

3 - follow the orders

(3) written
9/6/25

9/6

MEDICATION CHART

PLEASE CONFIRM PATIENTS NAME, DIAGNOSIS BEFORE PROCEEDING FOR MEDICATIONS

Name of Medicine with Dosage and Route

Date Time

No Rx

Sypp. Zinc (5ml/20mg)

(P/P) 5ml OD x 14 days

Date Time

5/6 8 AM

6/6 20 A

7/6 11

8/6 2

9/6 2

10/6

11/6

12/6

13/6

14/6

Stomach

NPO

1

2

2

Sypp Pem (5ml/125mg)

5ml SOS

Date Time

10/6

GRS

E/D Mycin

BE TDS x 5 days

Date Time

10/6

11/6

12/6

13/6

14/6

1

2

2

2

2

2

(Renewed)

E/D Mycin

(BLE) TDS

Date Time

15/6

16/6

17/6

8

2

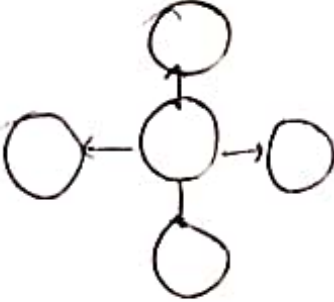

2

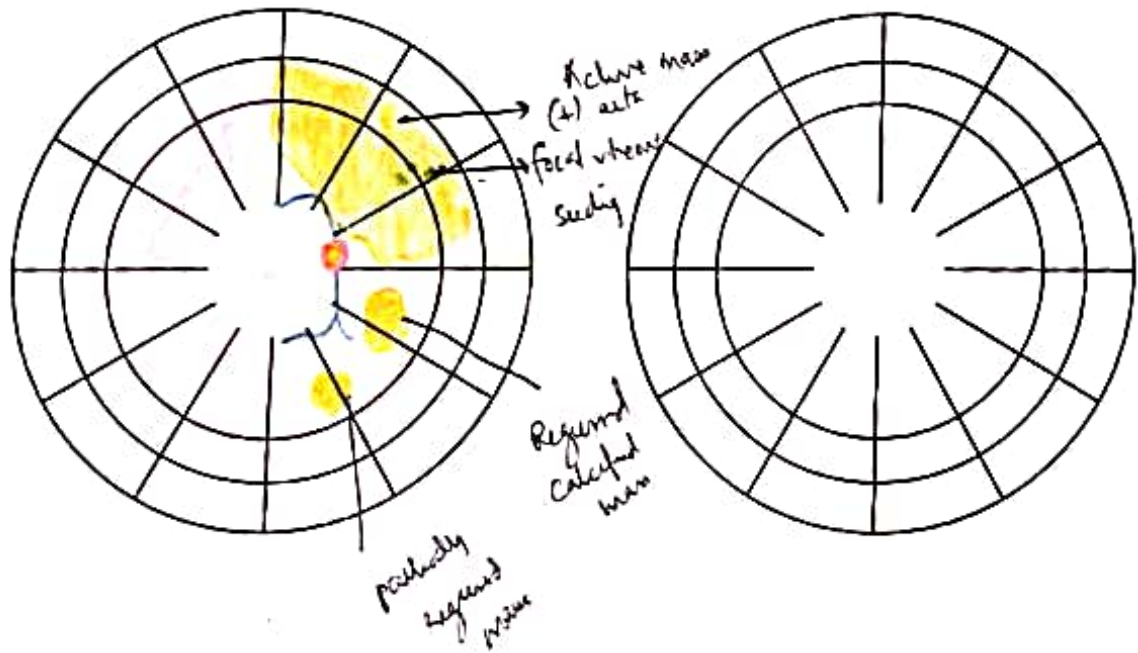
2

Date Time

Date Time

Date Time

DARK ROOM EXAMINATION	RIGHT EYE	LEFT EYE
Preliminary Examination		
Refraction Under Cycloplegic		Enucleated
OPHTHALMOSCOPY	<p>Globe not Media clear.</p> <p>Active mass (+) Superiorly with focal vitreous seeds</p> <p>Regressed calcified mass (+) nasally</p>	
<ul style="list-style-type: none"> (i) Distance Direct (ii) Direct Ophthalmoscopy <ul style="list-style-type: none"> Media Disc, Vessels A. V. Crossing Periphery Macula (iii) Indirect Ophthalmoscopy 		



डा० राजेन्द्र प्रसाद नेत्र विज्ञान केन्द्र
Dr. Rajendra Prasad Centre for Ophthalmic Sciences
A.I.I.M.S.
 Ansari Nagar, New Delhi-110029

Section _____
 Jr. Resident Dr. _____

Consultant Dr. Radeep Verkatoh Sr. Resident Dr. Naibara

C.R. No. _____ O.P.D. No. _____ Sp. Clinic No. _____ Ward / Bed No. 12/7

DR. RAJENDRA PRASAD CENTRE FOR OPHTHALMIC SCIENCES

UHID: 107475311 Date: 24/05/2025 11:44:53 AM

CR No. R-022459-25 Ward Name: RPC 1A Bed No: 127

Name: MR. SATYAM Unit In-charge: Dr. Profulla K Mahtrana Unit-VI

Age: 11 Y 3 M 29 D 04

SI: VIBHUTI ACCOUNTS-21-13004/202526 RS 140

Address: 54/3005A COLONY LONT BHAZIABAD UTTAR PRADESH



Age _____ Sex _____ Nationality _____

Family Income _____ Single / Married _____

Permanent Address _____

Occupation _____

D. A. _____ Time _____

D. D. _____ Time _____

Previous Admission / CR No. _____

Admission-Routine / Emergency / EHS / _____

Local Address _____

Tele No. _____

DIAGNOSIS	Primary	2nd	3rd	Code No.
Right Eye VA: Follows objects IOP: Doubly (~)	RE Gray B → C		RB	1) No SI 2) 3)
Left Eye VA: IOP:	LE Enucleated (gp E)		NR HRF	1) 2) 3)

Medical / Operation Treatment _____

Result : Cured / Relieved / Stationary / Failure _____

Photographs No. _____

X-Ray No. _____

Histopath Report No. _____

Flg

DR F	ENTRE FOR OPHTHALMIC SCIENCES
ID: 10 2311	DATE 24/05/2025 11:44:53 AM
CR No. IR 25	Ward Name: RPC 1A Bed No: 12
Name: MR. SATYAM	Unit In-charge: Dr. Prafulla K. Mehrotra Unit-VI
Age: 1 Y 7 M 19 D 04	ACCOUNTS-21-13004/202526 RS 140
S/O VISHNU	Address: 540, POOJA COLONY, LONI GHAZIABAD, UTTAR PRADESH

विज्ञान केन्द्र
 Ophthalmic Sciences
 नई दिल्ली- 110029
 Ophthalmic Sciences, New Delhi-110029
 REFERRAL RECORD

देवाहिक स्थिति Marital Status	के.पं.सं. C.R. No.
व्यवसाय Occupation	धर्म Religion
	स्थिति Status

Referred by Dr. Dr. Sanmit Anwar
 Unit 6, RP G. H. S. Requesting Doctor

to Dr. Prof. Roshni Sehgal, Pediatric Oncology
 Consultant & Specialty

Findings : Date : 11/6/2025

Respected Ma'am,
 We are referring patient of
 RE Multifocal Group B RB
 LE Group E RB

Diagnosis or Impression :
 left eye was enucleated. no RT
 Patient has received 6 cycles of chemo,
 now planned for RE single drug IAC
 but, is delayed in view of logistic reasons for
 another 2 weeks.

Recommendations: we request you to kindly review the patient
 for augmented iv chemotherapy to the patient.

get IAC.
 pt. admittance since 20/5/25 treatment
 pt. is getting antineoplastic for treatment
 now Indian Cancer Society for IAC
 please arrange regiments for IAC
 from this fund. There should
 be no delay ~~is not~~
 Thank you regard
11/6/25

Thanking you
Sanmit Anwar



Dr. Roshni Sehgal
 Consultant/Pediatric Oncology
 Department of Pediatric
 All India Institute of Medical Sciences, New Delhi-110029

दिनांक / Date	25/5	26/5	27/5	28/5	29/5	30/5	31/5	1/6	2/6	3/6	4/6	5/6	6/6
समय / Time	6:00	6:00	6:00	6:00	6:00	6:00	6:00	6:00	6:00	6:00	6:00	6:00	6:00
नब्ज / Pulse													
ताप / Temp													
180	42	107.6											
160	41	105.8											
140	40	104.0											
120	39	102.2											
100	38	100.4											
80	37	98.6											
60	36	96.8											
40	35	95.0											
संख्यात्मक दर्जा पैमाना / Numeric Rating Scale	10												
	8												
	6												
	4												
	2												
	0												
40	35	95.0											
श्वसन दर / Respiratory rate													
घन / Stool													
मूत्र / Urine													
घा. प्रमाण / F INTAKE													
आउट प्रमाण / F OUTPUT													

दर्द पैमाना / Pain Scale

Date	START		DRUG / DOSE / ROUTE / INFUSION RATE	END	
	TIME	VITALS		TIME	VITALS

STAT / AS REQUIRED DRUGS & INFUSIONS

	RIGHT	LEFT
PUPIL		
Size	2 - 3 mm	
Shape	Circular	
Position	Central	
Synechia		
Reaction to direct light	D+	
Consensual		
Accommodation		
LENS		
Transparency	Appears clear	Enucleated
Position		
Capsule		
RETICULAR		
State	Appears clear	
Opacities		
INTRAOCULAR TENSION		
Digital	Digitally (2)	
Instrumental, Schiottz		
Applanation		
BIOMICROSCOPIC FINDINGS (Digrams)		

SUMMARY

Admission Notes

admission by Junior Resident based on history, physical findings and investigations indicating line of the treatment and differential diagnosis

JAC conflictive

systemic -

- ophthalmic A. vasospasm
- spirochet neurosyphilitic
- nausea, vomiting, alopecia, skull immobility

ocular eye -

- reticular edema
- blepharospasm, keratic precipitates
- epithelium

IVC - 6 cycles (AOCV) - last Nov 2024

(1) Emulectin Lho - March 2025

Review notes by the Senior Resident

Signature

(R) Group B → C RB

No ST

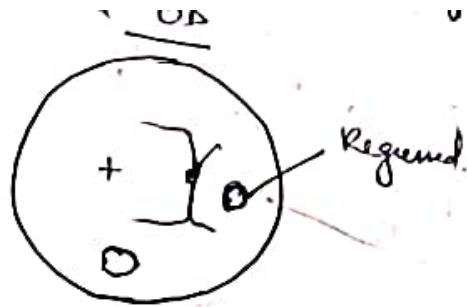
(L) Emulected

Plan: (R) Single Drug JAC

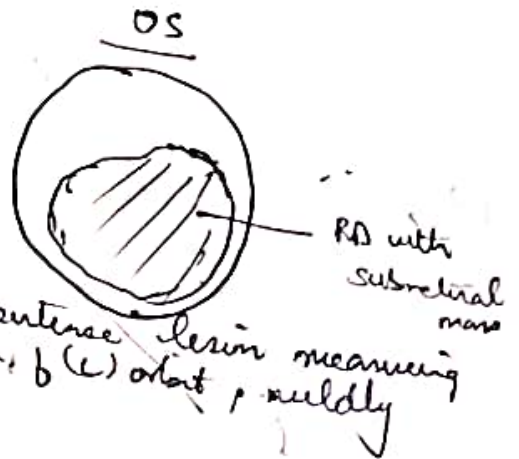
JCA

Signature

main



(HDCOV)



29/8/24: T1W isointense, T2W hypointense lesion measuring 7 x 8.5 x 7mm in posterior aspect of (L) orbit, mildly heterogeneously enhancing lesion.

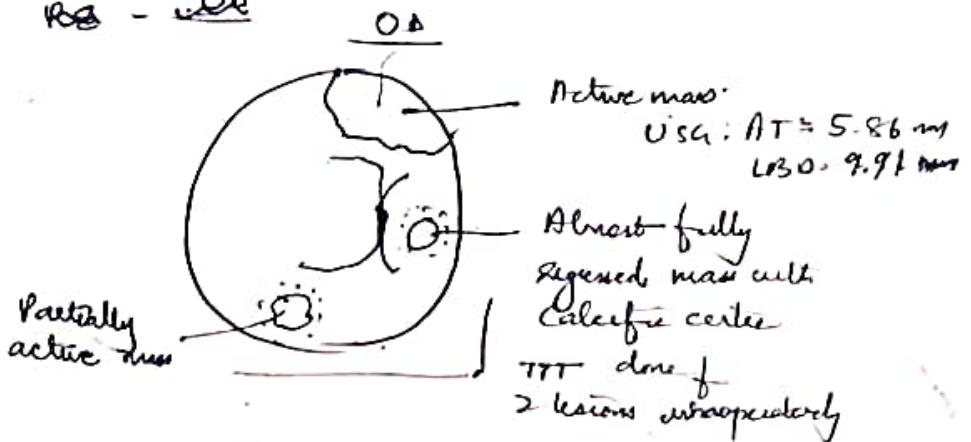
18/9/24: NRC ↓ Unit 6: LE: T2 hypointense mass in posterior segment, minimal enhancement, coats (N), ON - No enhancement & thickening. RE: Small T2 hypointense nodules, non-enhancing in superonasal anterior segment, ON - (N)

Patent was planned and posted twice for LE Enucleation but cancelled. ^{twice} 1/1/25 URT & neotropina, Chemotherapy continued. S/P 6 cycles of chemo (HDCOV) start in November 2024

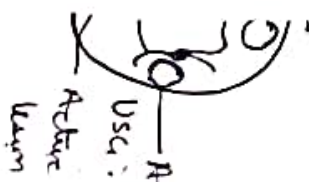
20/1/25: NRC ↓ Unit 6:-
 RE: Small T2 hypointense lesion in SN orbit? Calcific foci
 LE: Mass limited to globe no subretinal extension
 B/L optic nerves - wms, pineal gland - wms

18/3/25: RB - wms


TTT :-
 Power 250 mw
 Duration 29000 ms
 Wavelength: 50 nm



LE Enucleation + P implant & AN done. lateral cathodomy, cathodomy, culture, histology etc



all eyes & cal. photoph. seen with a globe with spinal lesion
 18/3/25 RB - wms
 18/3/25 RB - wms
 18/3/25 RB - wms

LOCAL EXAMINATION	RIGHT	LEFT
EYE BALLS Size, Shape Position Direction Movements Cover test Convergence	Ⓝ Size - Axial - 	Ⓝ size
EYE LIDS Position Palpebral aperture Movements, Skin Margins, Cilia Lashes, Canthi	Ⓝ position Ⓝ palpebral aperture No ectropion/ entropion/prosion	Ⓝ position Ⓝ palpebral aperture No ectropion/entropion/ prosion
TEAR DRAINAGE SYSTEM Lacrimal puncta, Lac. Sac : Lacrimal Gland Nasal check up	Puncta apposed to globe Regularly wet to	Puncta apposed Conjunctiva healthy
CONJUNCTIVA Discharge, congestion. Follicles Papillae Sclera Iris Pupil Lens Vitreous Retina Macula Optic disc	No discharge No congestion NO FB	Conjunctiva healthy Thyroid & conjunctiva in situ

46

DR. RAJENDRA PRASAD CENTRE FOR OPHTHALMIC SCIENCES		
UHID: 10*4*5311	Date: 24/03/2025 11:44:53 AM	
CR No.: R 021459 24	Ward Name: RPC 1A	Bed No: 127
Name: MR. SATYAM	Unit In-charge: Dr. Prafulla K Maharni	
Age: 1 Y 1 M 29 D 34	Unit-VI	
	ACCOUNTS-21-13004/202526	RS 140
E/O VIBHUTI		
Address: 542, POOJA COLONY, LONI, OHAZIABAD, UTTAR PRADESH		

नेत्र विज्ञान केन्द्र
for Ophthalmic Sciences
थान, नई दिल्ली- 110029
Sciences, New Delhi-110029
ULTIATION RECORD

एम.आर.-9
M.R.-9

वैवाहिक स्थिति	के.पं.सं.
Marital Status	C.R. No.
व्यवसाय	धर्म
Occupation	Religion
	स्थिति
	Status

Referred by Dr. SK ophthalmology to Dr. SK Inada ~~ophthalmology~~ Ph.D.
Requesting Doctor Consultant & Specialty

Findings : Date : ~~18/3/25~~ 5/6/25

Reported in medical
history see in pt. r

(R) Anus B. Hemorrhoids
(C) Hemorrhoids

Diagnosis or Impression :

Parents do loose stools in child -
3 times since ~~today~~ yesterday evening.
kindly evaluate & advise
regarding further management.

Recommendations:

[Signature]
Rajendra Prasad

NURSING NOTES

Received from OS at 2:25pm.

BE CUA ↓ GA

11/6/25 Gam: vitals stable or

12/6/25 6AM vital stable or

13/6/25 Gam: vitals stable or

14/6/25 6AM vital stable or

15/6/25 6AM - vital stable

16/6/25 6AM - vital stable

17/6/25 6AM vital stable

fasted for IAE on 17/6/25

repost 12^{mm}
Send to cath lab on call