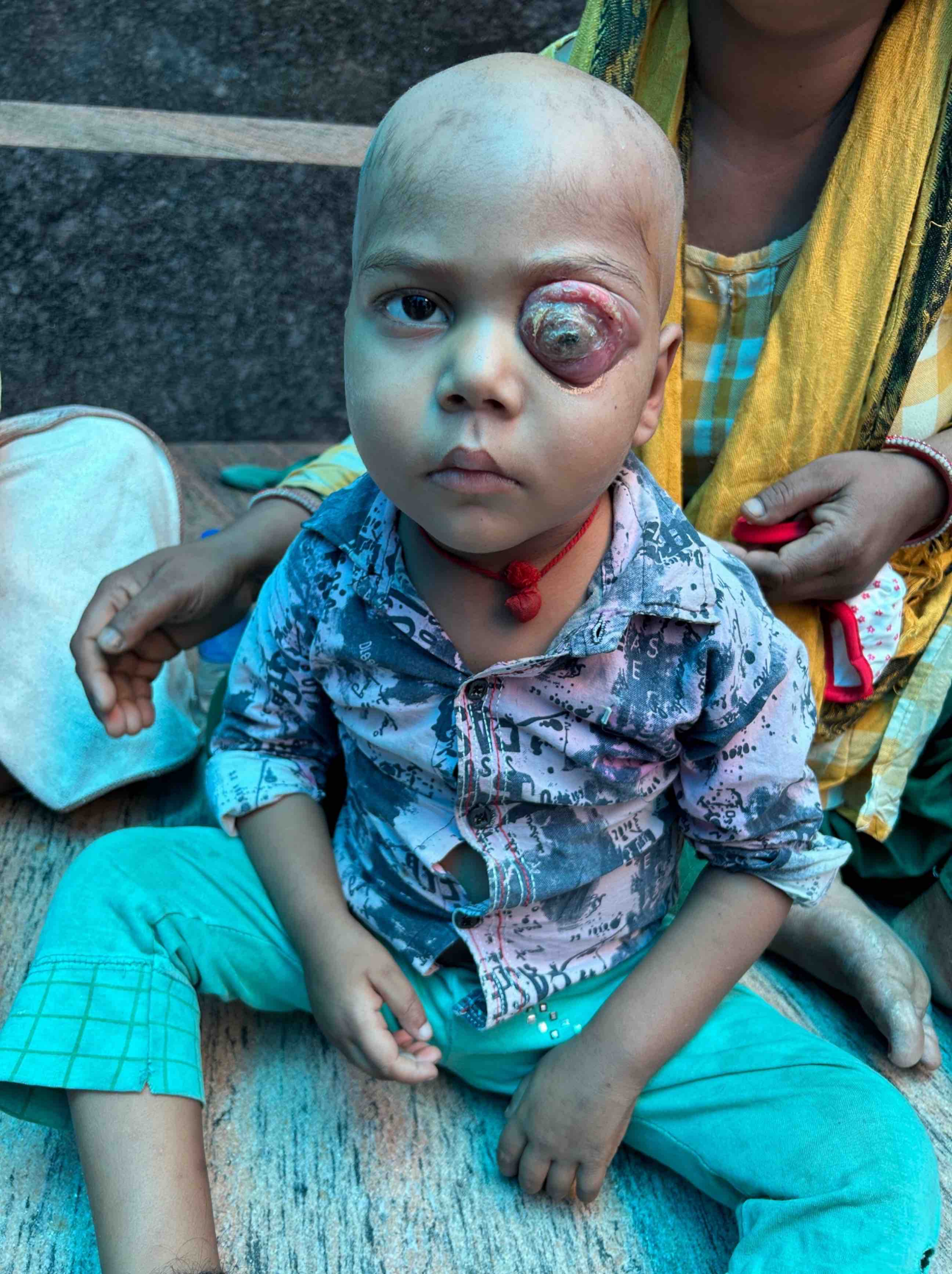
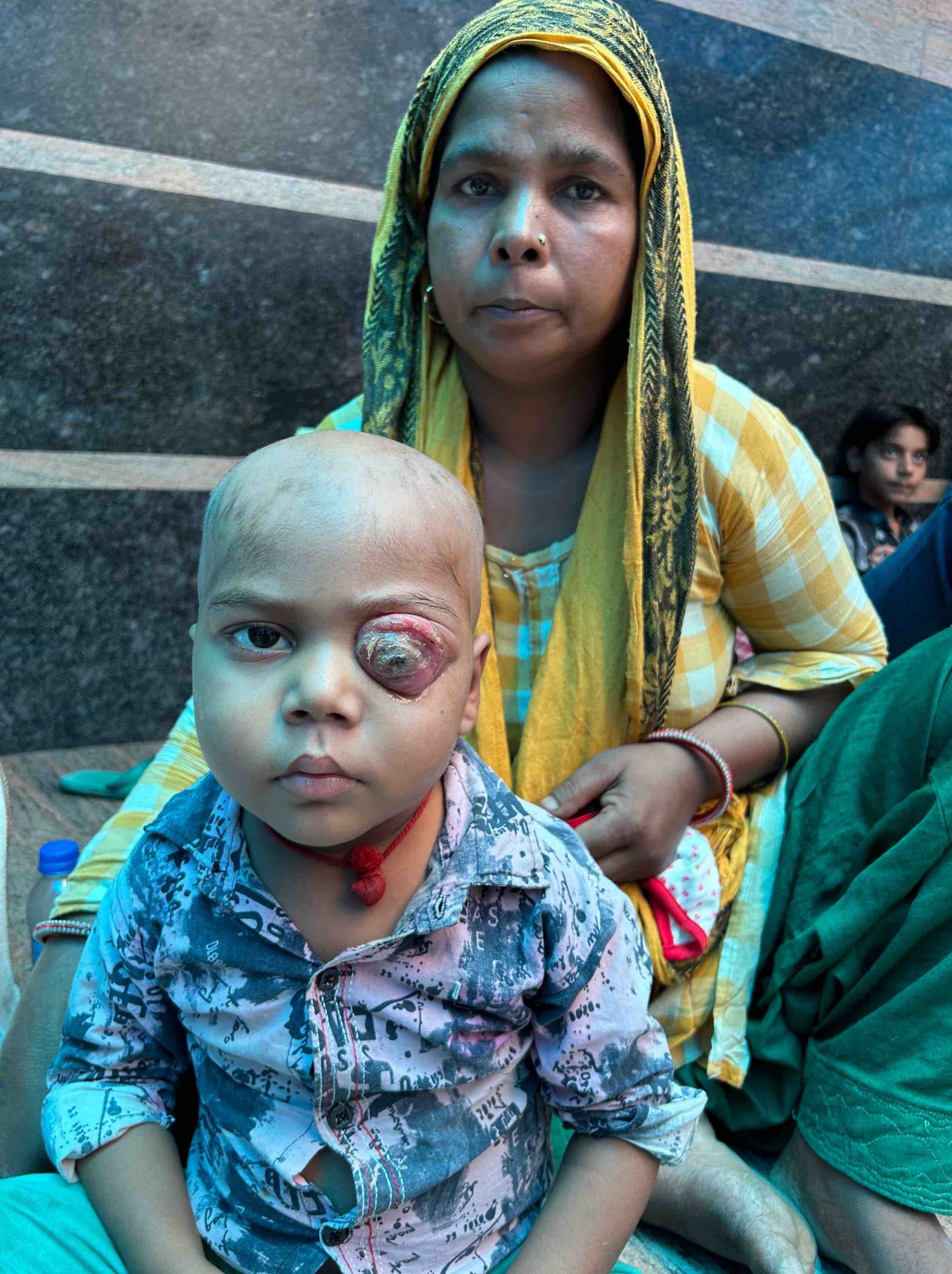






प्रयोगशाला अबुर्द विज्ञान, डॉ भीमराव अम्बेडकर संस्थान रोटरी कैंसर अस्पताल
अखिल भारतीय आयुर्विज्ञान संस्थान नयी दिल्ली -110029
LABORATORY ONCOLOGY, Dr B.R.A. Institute Rotary Cancer Hospital All India Institute
of Medical Sciences, New Delhi-110029

UHID:	105421237	Reg Date :	07/04/2021 08:51 AM
Patient Name :	Mr. UDIT KUMAR	Age :	4 years 3 months 7 days
Sex :	Male	Unit Name :	Unit-III
Department :	Paediatrics	Sample Collection Date:	10/05/2023 08:51 AM
Unit Incharge :	Dr. S. K. KABRA	Lab Sub Centre:	Lab Oncology (IRCH)
Lab Name:	Lab Oncology	Report Generated Date:	16/05/2023 08:47 PM
Sample Received Date:	10/05/2023 03:09 PM	Recommended By:	Dr. Dilip SR Paeds
Dept / IRCH No:	20210030006097		
Lab Reference No:	1529		
Ward Name:	DAY CARE PEDS MCH GF		

Sample Details : LOI-100523014-BP (Bone Marrow)

BMA BMT PS

Report: Bone marrow preparation shows only few marrow particles in background of blood.

Repeat bone marrow aspirate if indicated.

Peripheral smear is poorly spread, not suitable for comment.

Conclusion

Senior Resident: Dr.Rakesh Sunda

Consultant Dr Amar Ranjan

This is an electronically generated report, authorized signature is not required. The test reports have been authenticated.
Partial reproduction of the report is not permitted.

Authorized Signatory



प्रयोगशाला अबुर्द विज्ञान, डॉ भीमराव अम्बेडकर संस्थान रोटरी कैंसर अस्पताल
अखिल भारतीय आयुर्विज्ञान संस्थान नयी दिल्ली -110029
LABORATORY ONCOLOGY , Dr B.R.A. Institute Rotary Cancer Hospital All India Institute
of Medical Sciences , New Delhi-110029

Hard Print

UHID:	105421237	Reg Date :	07/04/2021 08:51 AM
Patient Name :	Mr. UDIT KUMAR	Age :	4 years 3 months 7 days
Sex :	Male	Unit Name :	Unit-III
Department :	Paediatrics	Sample Collection Date:	10/05/2023 08:51 AM
Unit Incharge :	Dr. S. K. KABRA	Lab Sub Centre:	Lab Oncology (IRCH)
Lab Name:	Lab Oncology	Report Generated Date:	15/05/2023 08:42 PM
Sample Received Date:	10/05/2023 03:19 PM	Recommended By:	Dr. Dilip SR Paeds
Dept / IRCH No:	20210030006097		
Lab Reference No:	674		
Ward Name:	DAY CARE PEDS MCH GF		

Sample Details : LOI-100523013-CS (CSF)

CSF For Morphology

C-674/23.

CSF cytospin smear is acellular.

Senior Resident:- Dr.Rakesh Sunda

Consultant Dr G Smeeta

REMARKS:-

This is an electronically generated report, authorized signature is not required. The test reports have been authenticated. Partial reproduction of the report is not permitted.

Authorized Signatory



Department Of Pathology
All India Institute Of Medical Sciences
Delhi

Tel: +91-11-26588500/26588700; Fax: +91-11-26588500/26588700

Patient Name: **Udit kumar**
F/H Name: **chaterpal**
Age/Sex: **2 Y/Male**
Clinic/Dept/Unit: **N/A/Unit 1**
Reg Date: **10-05-2023**

Acc. No: **2321306**
Hosp. Reg. No.: **105421237**
UHID No.: **---**
Consultant Incharge: **Dr. N/A**
Reporting Date: **18-05-2023**

Histopathology Report

Report Findings:

Received two specimens:

- I) "Bone marrow biopsy from right side" is fragmented and subcortical and predominantly comprises of cartilage with a single interpretable intertrabecular space showing sparse hematopoietic elements. The biopsy is inadequate for opinion on metastasis from retinoblastoma.
- II) "Bone marrow biopsy from left side" comprises of cartilage, fibroadipose tissue and scant subcortical bone with procedural hemorrhage. Scant erythroid and myeloid lineage cells are seen in the intertrabecular spaces. There is no evidence of metastasis from retinoblastoma in the biopsies.

NOTE: The patient is a known case of retinoblastoma, vide clinical history.

Reporting Incharge: **Dr. Aanchal Kakkar**

Reporting SR: **Dr. Hena Khandakar**
Verify By: **Dr. Hena Khandakar**



Department Of Pathology
All India Institute Of Medical Sciences
Delhi

Tel: +91-11-26588500/26588700; Fax: +91-11-26588500/26588700

Patient Name: Udit kumar	Acc. No: 2321306
F/H Name: chaterpal	Hosp. Reg. No.: 105421237
Age/Sex: 2 Y/Male	UHID No.: ---
Clinic/Dept/Unit: N/A/Unit 1	Consultant Incharge: Dr. N/A
Reg Date: 10-05-2023	Reporting Date: 18-05-2023

Histopathology Report

Report Findings:

Received two specimens:

- I) "Bone marrow biopsy from right side" is fragmented and subcortical and predominantly comprises of cartilage with a single interpretable intertrabecular space showing sparse hematopoietic elements. The biopsy is inadequate for opinion on metastasis from retinoblastoma.
 - II) "Bone marrow biopsy from left side" comprises of cartilage, fibroadipose tissue and scant subcortical bone with procedural hemorrhage. Scant erythroid and myeloid lineage cells are seen in the intertrabecular spaces. There is no evidence of metastasis from retinoblastoma in the biopsies.
- NOTE: The patient is a known case of retinoblastoma, vide clinical history.

Reporting Incharge: Dr. Aanchal Kakkar

Reporting SR: Dr. Hena Khandakar
Verify By: Dr. Hena Khandakar



प्रयोगशाला अबुर्द विज्ञान, डॉ भीमराव अम्बेडकर संस्थान रोटरी कैंसर अस्पताल
अखिल भारतीय आयुर्विज्ञान संस्थान नयी दिल्ली -110029
LABORATORY ONCOLOGY , Dr B.R.A. Institute Rotary Cancer Hospital All India Institute
of Medical Sciences , New Delhi-110029

UHID:	105421237	Reg Date :	07/04/2021 08:51 AM
Patient Name :	Mr. UDIT KUMAR		
Sex :	Male	Age :	4 years 3 months 7 days
Department :	Paediatrics	Unit Name :	Unit-III
Unit Incharge :	Dr. S. K. KABRA	Sample Collection Date:	10/05/2023 08:51 AM
Lab Name:	Lab Oncology	Lab Sub Centre:	Lab Oncology (IRCH)
Sample Received Date:	10/05/2023 03:09 PM	Report Generated Date:	16/05/2023 08:47 PM
Dept / IRCH No:	20210030006097	Recommended By:	Dr. Dilip SR Paeds
Lab Reference No:	1529		
Ward Name:	DAY CARE PEDS MCH GF		

Sample Details : LOI-100523014-BP (Bone Marrow)

BMA BMT PS

Report: Bone marrow preparation shows only few marrow particles in background of blood.

Repeat bone marrow aspirate if indicated.

Peripheral smear is poorly spread, not suitable for comment.

Conclusion

Senior Resident: Dr.Rakesh Sunda

Consultant Dr Amar Ranjan

This is an electronically generated report, authorized signature is not required. The test reports have been authenticated.
Partial reproduction of the report is not permitted.

Authorized Signatory

संख्या/Serial No.

1102059

ओ.पी.डी सं./OPD No.

यूएचआईडी सं./UHID No. 20230377742

जारी करने की तारीख/Date of Issue

18/5/23

टोकन संख्या /Token No.

19

अखिल भारतीय आयुर्वेद संस्थान

ALL INDIA INSTITUTE OF AYURVEDA



आयुष मंत्रालय, भारत सरकार के अंतर्गत स्वायत्त संस्थान
(An Autonomous Organization under the Ministry of Ayush, Govt. of India)

गौतमपुरी, सरिता विहार, मथुरा रोड, नई दिल्ली-110076

Gautampuri, Sarita Vihar, Mathura Road, New Delhi-110076

(एन ए बी एच प्रत्यायित अस्पताल)

(NABH Accredited Hospital)

नाम/ Name :

Chatoopal

आयु/ Age :

36

पुरुष/ Male :

स्त्री/ Female :

अस्थायी रोगनिदान/ Provisional Diagnosis :

दिनांक/Date

संक्षिप्त इतिवृत्त/
Brief History

DM (HTN) IT

चिकित्सा/Treatment:

B.P - 115/75 mmHg

Pulse - 80/min

wt - 52 kg

do-
- Mass coming out from anus.
- Bleeding per rectum. x 6 months.
- Body aches.
- ~~Hand~~ Tingling sensation in Lt. arm.

① Kankayan vati

1 - 1 - 1

② Jatyadi tail for LIA.

③ M. Swadishtha. Virchan churna.
3gm HS to 1.wt.

④ Abhyarishtha. 15ml - 15ml.
to eq water, AIF.

पैदानिक परीक्षण /Investigations

पथ्य/Do's

Signature of Medical Officer

अपथ्य (परहेज)/Don'ts

Department of Integrative Medicine

VMM

दीप

Patient Details

C.K-POD-54084

Name : Udit Kumar

Age / Gender : 2 1/2 y / M

Father's Name : Chattarjal

Address : Vill : Shahedpur Jaitam, Tehs
Lilla Sambhal UP

Contact No : 9756191549

POC / PCSC No.: 143/21

Diagnosis : (L) EORB

Remarks :

Ag..... neg
HIV Status..... neg
HBV 0.6/9 |
MT..... neg

Ant HCV → neg



Diagnostic Work UP & Risk Stratification

① EORB

MRI : ② WNL

① - Intraocular mass
defining & enhancing
homogeneous ⊕
ON ⊕ (~ 4mm)

Bone Marrow Aspirate : ②. No mets

Bone Marrow biopsy : → Report to be collected

CSP : Negative

Bone scan : To be done

↳

Name of treatment protocol

High dose CEV.

25/8/21

Go to EORB

Came for cycle 3

Bone scan → Not done

Bone Marrow Biopsy → Report to be collected

Bone Scan → To be done
OT/PT. 39/22/0.13

Plan

10.3 > $\frac{800}{2782}$ < 549000 urea / Creat: 14/02

① To redate bone scan → 1/9/21
↳ Hu after redating

② Hu on ~~28/8/21~~ 06/9/21 Sat 9AM → Monday
↓ Prof R. Seth

③ Chemo - 2/9/21.

hi VCR 0.25mg iv push

ⓓ₁

hi Carboplatin 280mg / 200ml NS iv over 2hr

ⓓ₁

hi Etoposide 120mg / 100ml NS iv over 1hr

ⓓ₁

ⓓ₂

डॉ. रचना सेठ
DR. RACHNA SETH
नियंत्रण / Professor
कक्षा / Department of Oncology

MLC / NON - MLC

अखिल भारतीय आयुर्विज्ञान संस्थान
ALL INDIA INSTITUTE OF MEDICAL SCIENCES
अंसारी नगर, नई दिल्ली - ११००२६
Ansari Nagar New Delhi - 110029

UHID No. 105421237

ADMISSION SLIP

Dated 26/05/23

AADHAR No.

Please admit Shri. / Smt. / Dr. / Miss Udit

Age 2.5 Sex M in ward McBayan Under Unit Bed III

and Senior Resident of the Unit SR III whose Provisional

diagnosis is (D) FOMB (in block letters)

C. A. O./ Hosp. Enquiry
Code No.....

Signature & Stamp of the Admitting Medical Officer

Name of the Admitting M.O.....

Designation of Admitting M.O.....

Please advise patient / attendant to fill the details on the back of slip.

6/9/21

kt EORB

3 cycle completed
↓ 10 ml

ing HBV oc dose
Cela ble dose

→ photology
→ no osculules
on septum

- Received 3 cycles of HO-cev

- Bone scan - dated as 15/9/21

Adv

o Collect Bone marrow biopsy

• No septum

19
am!

06.09.21

CBC - (2)

LFT (2)

KFT (2)

BM biopsy - (2)

CSC - (2)

Next cycle due on 30/9/2021.

To R/w in OPD on 29/9/2021 =

CBC/RFT/LFT.

Asma
SR
SENIOR RESIDENT
Department of Pediatrics
All India Institute of Medical Sciences
Department of Pediatrics-110029
All India Institute of Medical Sciences
Ansar Nagar New Delhi-110029

10/9/21.

40 EORB

Presented to emergency ~~tomorrow~~ with
fever

Given IVF correction
for dehydration

+ IVAb

40

- o fever
- o loose stools
- o rough

6 No neutropenia

5pm

13/5/23

① EDAB (defaunax)

Interview

- apathetic > 48 hrs.
- CBx to be sent
- bloods - awaited
- petechial rash improved
- vitals stable
- HR = 96/min
- RR = 25/min
- PMI BRAS ⊕
no added sounds

• no fresh complaints

HA = 12mg


Adv.

- to continue inj. Piptaz/Amika from Gauranagar.

- Egg plan (125%) 2nd 50%

- Rf 8 in MCB DC tomorrow for bloods & need for transfusion

Satyam



Plan

- 4c bloods



13/5/23

→ Fournier's abscess
 child still neutropenic (ANC 200)
 continue antibiotics in GIBF
 ↳ repeat CBC tomorrow → if ANC > 1000 stop

Udit

① gp E RB

defaults - 1 kg

Part Augmentations

wk # 3 8

CG MRI → CNRC

① gp E

no

optu

② involunt

③

introduce part

no mets

but

ANC

- 950

16/5

FN -

Revised

8-9

4800

69K

850

Getto -

②

study

Optimise

source

4 days

Adv

- stop

- Syp

- w

- to

iv antibiotics

augmentations

collect

Review

20/5/23

Bm

exam

($\frac{228}{5}$)

3.5ml

BSD x 5 days

with

with

- Pandey

Reports

reports

om

CSC / LFT / RFT

20/5/23

Regime not maintained
encouraged
pharmacy - BMA / B / CSF / MEF.

9.7 $\frac{20,200}{4,560}$ 2.59L

Urea Cul ②

Bl 0.14

ECHO ②

- Chemo dated 26/05/23

Inj emul 2mg + dex 2mg

10f DNS 1:100 KU @ 60ml/hr x 5 hr
Inj Utk - 0.7mg IV slow push

Inj Cyclophosphide 750mg in 100ml NS
over 1 hr

Inj Docetaxel 15mg in 100ml NS
over 1 hr
Plasma 200mg
0.35h



Inj GBR 6mg S-CON
x 5 days

AIIMS GENERAL PHARMACY
NAME: ✓
DATE: 20/6/23 (Bowel)
SIGN: _____

✓ Tab emul 2mg PO TDS

✓ Tab dex 2mg 1/2 PO BD

✓ Tab Pantoprazol PO OD

R/W: 14/06/23

CRS/MS/MST

30mg Septra
40mg (Sul)
6ml Poast-ds

[Handwritten signature]

SENIOR RESIDENT
Department of Pediatrics
All India Institute of Medical Sciences
Ansari Nagar, New Delhi-110029



भारत सरकार

Government of India



छत्रपाल

Chatrapal

जन्म तिथि / DOB : 01/01/1987

पुरुष / Male



5603 3395 1526

आधार - आम आदमी का अधिकार



भारतीय विशिष्ट पहचान प्राधिकरण

Unique Identification Authority of India

पता:

आत्मज: राम कुमार, सैदपुर जयराम,
संभल, संभल, उत्तर प्रदेश, 244302

Address:

S/O: Ram Kumar, Saidpur
Jayram, Sambhal, Sambhal, Uttar
Pradesh, 244302

5603 3395 1526



1947
1800 300 1947



help@uidai.gov.in

WWW

www.uidai.gov.in