

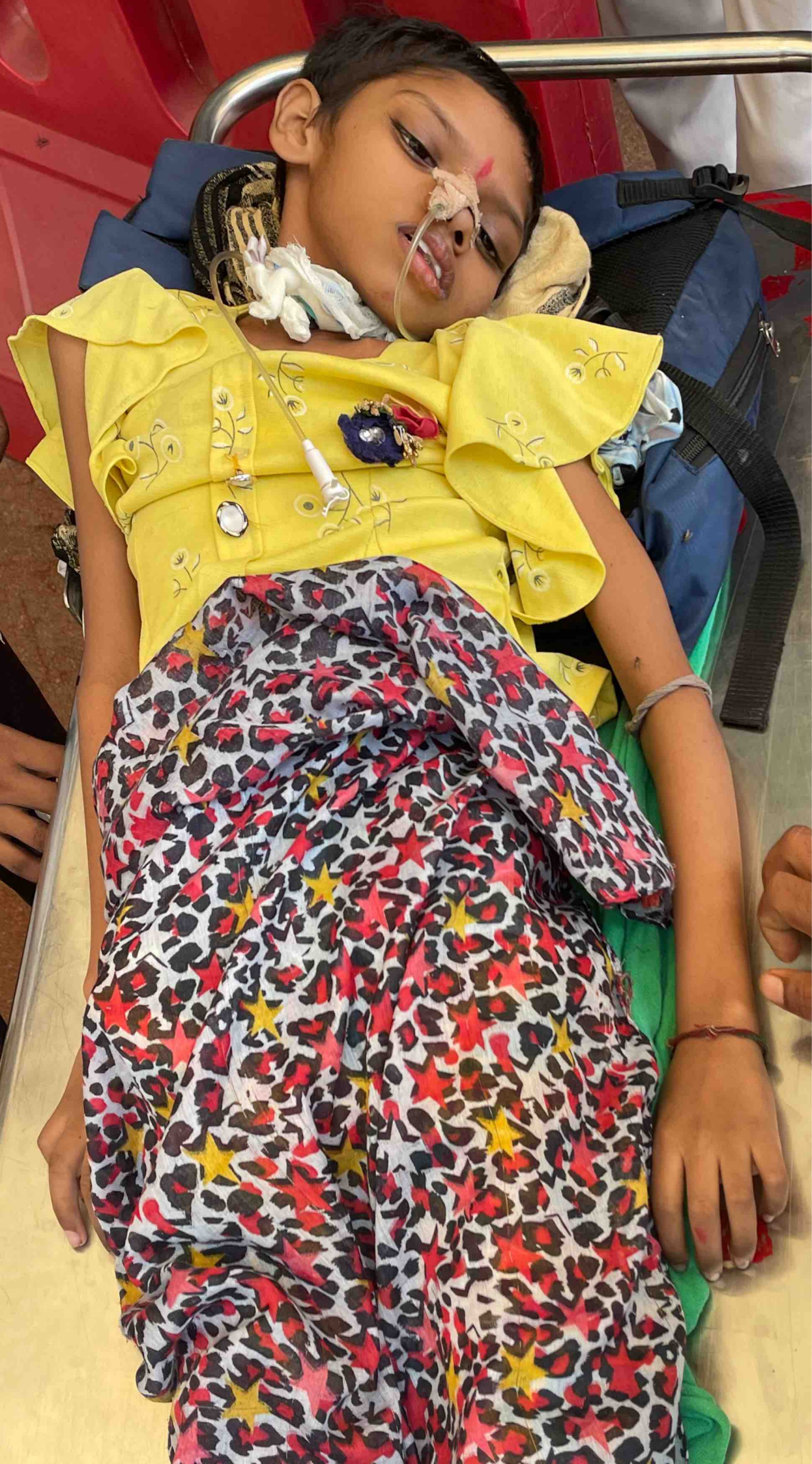

DR. B.R.A. IRCH
& IIMS, NEW DELHI

Welcomes
All Cadre employees of IRCH
Patients & their relatives
on

Celebration
01.04.2022 to 15.04.2022

Guests: Employees
Faculty & Management
Organized by:
Department of Nursing
IRCH & IIMS, New Delhi





डा. बी. आर. अम्बेडकर संस्थान रोटरी कैंसर अस्पताल
Dr. B.R. Ambedkar Institute Rotary Cancer Hospital
अ.भा.आ. सं. अस्पताल / AIIMS HOSPITAL

OPR-6

बहि
उपचार के अंग

15

एकक/Unit _____

विभाग/Dept. _____

उप/Name

[Handwritten signature]

DR. B.R.A. ICH/AIIMS/NEW DELHI
Reg. Date: 10/11/2011
ICCH No. 211294
Chair No. 202201-96
UHD-10079024
Name: ANUSHKA KUMARI
DOB: 11/04/2002
Age: 19Y
Address: PUDA NAGLA, LATHA, SITTA, PRADINI, PUNJAB, INDIA

RT-117617
Date of Birth

निदान/Diagnosis

H/O multiple bleeds Post MPVP shot

दिनांक/Date

उपचार/Treatment

*25/4/22
7/5*

C/DW for H/O

- Review of POMRE report on sat (16/04/22) for opinion on hist treatment plan -> NOCLIN (Abroad Review)
- Review in ENT dept for tracheostomy con & plan.

16/4/22

Adv

- Neuro surgery review - Dr. Kedra
- Provisional date for AT [] 16/28
- Hist plan after MAZ whole spine screening
- Review on 23/4/22

DFET

Simulation

16 | 06 | 22

R: 28, 8:30am

CBC, LFT, KFT

अंगदान-जीवन का बहुमूल्य उपहार/ORGAN DONATION - A GIFT OF LIFE

O.R.B.O., AIIMS, 26588360, 26593444, www.orbo.org Helpline - 1060 (24 hrs service)

बाहर से आने वाले रोगियों के लिए धर्मशाला की सुविधा उपलब्ध है/Dharamshala facility is available for outstation patients

*14/5/2022
820-
OR*

(57)

21/5/2022

urgent
File to ROC

R7 was

Durgam
Sahas

→ clerk or 3-gupta

ill. poor GC

To start vet. chems → x 3 cycles
(to admit or R7 was)

↓
area of GC

Durgam

M/s Bed. - NA. (Area) m/s
Dr. S.

R/U Tomar. 25/5/2022
AT-ward for AT/ID admission
SAS



अखिल भारतीय आयुर्विज्ञान संस्थान, नई दिल्ली-110029
ALL INDIA INSTITUTE OF MEDICAL SCIENCES, NEW DELHI -110029

आपातकालीन विभाग

(DEPT. OF EMERGENCY MEDICINE)



UHID No:105795024

आपातकालीन नं. (Emergency No): 2022/030/0039421

दिनांक DATE: 24/05/2023

समय TIME: 05:55:19 PM

NON-SILC

नाम NAME: MISS. ANUSHKA KUMARI

आयु AGE: 9 years 3 months 19 days

लिंग/SEX: F

D/O: VIKASH KUMAR

पता ADDRESS: मकान संख्या H.NO: POTA NAGLA
शहर/प्रखण्ड CITY/BLOCK:
राज्य STATE: UTTAR PRADESH

POTA NAGLA
UTTAR PRADESH

गली / मुहल्ला STREET/MOH: EASTIA
पिन PIN: 207001

स्थान Location: Paediatrics Emergency
Criticality: Red / Yellow / Green

द्वारा BROUGHT BY: Relative: FATHER

Triage: Responsive/
Unresponsive

HR

/min

BP

mmHg RR

/min

SpO2

%

Shifted to Paeds/ Main/ New Emergency

Presenting Complaints

Primary Assessment (ABCDE) : Assessment Pentagon

Airway	Circulation	Disability
Open & stable: Yes/No If No.....	HR...../min	GCS.....
Breathing: RR...../min Efforts: Normal/Poor/increased	CFT.....sec.	Pupil size...../min
Auscultation: Air entry: Normal/poor/Differential	BP.....mmHg	Pupillary Reactions.....
Added sounds: None/Stridor/Wheeze/Crackles	Peripheral pulse: Poor/Good	Motor activity: Normal & Symmetrical/Asymmetrical/ Posturing/Flaccidity/Seizure
SpO2 on Room air.....	Central pulse: Poor/Good	Blood Sugar.....mg/dl
	Skin temp: Warm/cool	Exposure: Temp.....
	Others	Colour: Normal/pallor/cyanosis (mottled Any other skin lesions.....

Diagnosis



आपातकालीन विभाग



(DEPT. OF EMERGENCY MEDICINE)

UHID No:105795024

आपातकालीन नं.(Emergency No): 2022/030/0034253

दिनांक DATE: 07/05/2022

समय TIME: 10:58:43 AM

NON-MLC

नाम NAME: MISS. ANUSHKA KUMARI

आयु AGE : 9 years 3 months 2 days

लिंग/SEX : F

D/O : VIKASH KUMAR

पता ADDRESS: मकान संख्या H.NO: POTA NAGLA

गली / मुहल्ला STREET/MOH: EATHA

शहर/प्रखंड CITY/BLOCK:

पिन PIN: 207001

राज्य STATE: UTTAR PRADESH

दूरभाष सं. PHONE NO:

स्थान Location:

Paediatrics Emergency

द्वारा BROUGHT BY: Relative : FATHER

Criticality: Red / Yellow / Green

Triage: Responsive/
Unresponsive

HR

/min

BP

mmHg RR

/min

spO2

%

Shifted to Paeds/ Main/ New Emergency

P/O/C- medulloblastoma / MDPV skull (PNS- I/P/v)

Presenting Complaints

Admitted 6/2/22 to 18/3/22

Tracheostomy done on 21/3/22

currently displacement of TT tube ∴ night
no respiratory distress

Primary Assessment (ABCDE) : Assessment Pentagon

Airway	Circulation	Disability
Open & stable : Yes/No If No.....	HR...../min	GCS..... <u>E4 M6 V7</u>
Breathing: RR <u>22</u> /min	CFT..... <u>2</u> secs.	Pupil size..... <u>2mm</u> /min
Efforts: Normal/Poor/increased	BP.....mmHg	Pupillary Reactions..... <u>BBRL</u>
Auscultation:	Peripheral pulse: Poor/ <u>Good</u>	<u>Motor activity:</u>
Air entry:	Central pulse: Poor/ <u>Good</u>	<u>Normal & Symmetrical/Asymmetrical/</u>
<u>Normal/poor/Differential</u>	Skin temp. <u>Warm</u> /cool	<u>Posturing/Flacidity/Seizure</u>
Added sounds:	Others	Blood Sugar.....mg/dl
<u>None/Stridor/Wheeze/Crackles</u>		<u>Exposure:</u>
SpO2 on Room air..... <u>99%</u>		Temp.....
		Colour: <u>Normal</u> /pallor/cyanosis
		/mottled
		Any other skin lesions.....

Diagnosis

शरीरमाद्यं खलुधर्मसाधनम्

ENT SR to review for TT tube insertion

send to ENT
R No. 13

Handwritten signature

7/5/22

C/S/B ENT on call

Dr. Mahesh A JR ENT
Dr. Smile } SR ENT
Dr. Raiza } SR ENT

A case of medulloblastoma post surgery
Tracheostomised i/v/o prolonged intubation

21/2/2022 -

came with accidental T-tube removal,

PT PR - 130/100

SPO₂ - 98% @ RA

Under vision some uncuffed T-tube inserted,
secured with ties.

Adv

- Regular T-tube care

Regular suctioning
Chest Physiotherapy
T-tube change every
monthly
change peritoneal
gauze daily

J.P.

ENT SR.



अ० भा० आ० सं० अस्पताल / A.I.I.M.S. HOSPITAL
बहिरंग रोगी विभाग / Out Patient Department



अस्पताल के अन्दर धूम्रपान मना है / SMOKING IS PROHIBITED IN HOSPITAL PREMISES

शरीरमाद्यं खलु धर्मसाधनम्

एकक/Unit

विभाग/Dept.

नाम/Name

New Patient
Dept Reg. 2022/009/0008651

General/६ ०

ENT/Unit-III कमरा/Room: 4114-B
Days :
Name: Miss. ANUSHKA Queue No : N14
KUMARI १५ महिला/F
D/O VIKASH KUMAR Ph. 9528232014
UHID : 105795024 Date. 02/05/2022

OPR-6

No.

पता/Address

निदान/Diagnosis

दिनांक/Date

उपचार/Treatment

25/2022

Uro Medulloblastoma - (Post Surgery)

muscle lift (by Dr. R. S. Dr. Sivasai)

Current treatment 21/21 now - 21/21 no. of cycles
substituted.

of

On N-G feeds

1/2 of 500ml Urine 1-2 times daily

2022

7- tube chyl 500ml

airblast ad

7- tube chyl 500ml

- 15 chyl

(416)

applied

contain 7- tube core

CLEAN AND GREEN AIIMS / एम्स को यही संकल्प, स्वच्छता से काया कल्प

अंगदान-जीवन का बहुमूल्य उपहार / ORGAN DONATION - A GIFT OF LIFE

O.R.B.O., AIIMS, 26588360, 26593444, www.orbo.org Helpline - 1060 (24 hrs service)



meraaspatal.nhp.gov.in

हृदय वक्ष एवं तंत्रिका विज्ञान केन्द्र
ब० रो० वि०

अ० भा० आ० सं०, नई दिल्ली-110029

Cardiothoracic & Neurosciences Centre, O.P.D.
A.I.I.M.S., New Delhi-110029

दिनांक/Date 25/3/2022

विभाग
Deptt.

NS

NS 2022/017/0004105

Neuro Surgery-II

UHID: 105795024

Neuro Surgery

Date 12/04/2022 TUE, FRI

Slip

9Y 2M 7D

यू०एच०आई०डी०सं०

Name ANUSHKA KUMARI

/Female

UHID No.

D/O VIKASH KUMAR



105795

Consultant Room 10

Dr. Shweta Kedia

SR Room:

Registration Time: 8.30 AM - 10.30 AM

Adv:

→ to bring patient
on Tuesday OPD
29/03/2022.

→ TEMPI Brain

Dr. Sumit

5/2/22

→ IRCH OPD

Dr. Sumit
5/2/22

9/4/22

डॉ० सुनील गुप्ता/Dr. SUNIL GUPTA
वर आचार्य/Additional Professor
विकिरण अंतुर्विज्ञान विभाग/Dept. of Radiation Oncology
डॉ० बी० आर० ए० आई० आर० सी० एच०, अ० भा० आ० सं०
Dr. B.R.A. IRCH. (AIIMS)
नई दिल्ली-110029/New Delhi-110029

दिनांक
Date

29/3/2022

Adv:

→ IRCH OPD

→ RT/Foleys change
- NS-2 ward

→ CEMK 2 B2 en

Dr. Sundar

SPNSX

APP


19/5/22
20.6

Adv

→ IRCH OPD

[RT | change
TT | (28)

NS2 Ward





अखिल भारतीय आयुर्विज्ञान संस्थान, नई दिल्ली
ALL INDIA INSTITUTE OF MEDICAL SCIENCES, NEW DELHI

UHID:	105795024	Sex :	Female
Patient Name :	Miss. ANUSHKA KUMARI	Sample Received Date :	27/02/2022 10:52 PM
Age :	9 years 22 days	Department :	Neuro Surgery
Unit Name :	Unit-II	Unit Incharge :	Dr. S. S KALE
Lab Name:	Hematology	Lab Sub Centre:	Heamatology PT
Reg Date :	05/02/2022 09:20 PM	Sample Collection Date:	27/02/2022 06:19 PM
Report Generated Date:	28/02/2022 12:53 am	Dept / IRCH No:	0
Recommended By:	Dr. ASHWIN NSC	Lab Reference No:	0300

Sample Details : HPT-2702220353

Report

Test Name	Result	Comment	Normal Range
<u>PROTHROMBIN TIME (PT-INR)</u>			
PROTHROMBIN TIME(PT)	11.100 sec		9.70-12.70
INR	0.973		

Over All Comment :

Authorised Signatory

Verified By
sumeshkumar

Report Plain



प्रयोगशाला कायचिकित्सा विभाग
DEPARTMENT OF LABORATORY MEDICINE
रुधिर विज्ञान

Hematology
अखिल भारतीय आयुर्विज्ञान संस्थान, अंसारी नगर, नई दिल्ली-110029
All India Institute of Medical Sciences, Ansari Nagar, New Delhi-110029

UHID:	105795024	Sex :	Female
Patient Name :	Miss. ANUSHKA KUMARI	Sample Received Date :	27/02/2022 10:48 PM
Age :	9 years 22 days	Department :	Neuro Surgery
Unit Name :	Unit-II	Unit Incharge :	Dr. S. S KALE
Lab Name:	Hematology	Lab Sub Centre:	Hematology (Ward)
Reg Date :	05/02/2022 09:20 PM	Sample Collection Date:	27/02/2022 06:20 PM
Report Generated Date:	28/02/2022 12:19 am	Dept / IRCH No:	0
Recommended By:	Dr. ASHWIN NSC	Lab Reference No:	566

Sample Details : HMW-270222628

Report

Test Name	Result	Comment	Normal Range
<u>CBC PACKAGE</u>			
T.L.C	6.35 $10^3/\mu\text{L}$		4.00-11.00
NEUTRO	65.2 %		40.00-80.00
LYMPHO	20.8 %		20.00-40.00
MONO	9.9 %		2.00-10.00
EOSINO	3.5 %		1.00-6.00
BASO	0.6 %		1.00-2.00
NUCLEATED RBC	0.0		0.00-
RBC COUNT	4.22 $10^6/\mu\text{L}$		• 3.8 - 4.8 $10^6/\mu\text{L}$
HB	11.6 g/dL		• 12 - 15 g/dL
HCT	34.9 %		• 36 - 46 %
PLATELET COUNT	706 $10^3/\mu\text{L}$		150.00-400.00
MCV	82.7 fL		80.00-96.00
MCHC	33.2 g/dL		32.00-36.00
RDW CV	14.0		0.00-0.00
MCH	27.5 pg		26.00-34.00

Over All Comment :

Authorised SignatoryVerified By
drramjirao

Ht - 130 cm
Wt - 25 kg

(5)

22-3636 Dept. of Neurosurgery

Progress Notes

MEDICAL RECORD

NOTE DATED: 03/18/2022 11:36
LOCAL TITLE: NEUROSURGERY DISCHARGE NOTES
STANDARD TITLE: NEUROLOGICAL SURGERY NOTE
VISIT: 03/18/2022 11:36 DR OFFICE
DEPARTMENT OF NEUROSURGERY & GAMMA KNIFE, A.I.I.M.S., NEW DELHI
DISCHARGE SUMMARY

NOTE-Unless otherwise specified all dates mentioned in this note are in the formate MM/DD/YYYY

S.NO.:

UHID NO:105-79-5024

Patient Name : KUMARI, ANUSHKA Age : 9 Sex: FEMALE
S/O: WARD: NS3 BED NO: TR
Address : DAUDPUR DIST- SARAN, BIHAR, INDIA
Phone No. : 8521995243
Unit : 2
Consultant : DR SK

Assistant Surgeon 1st : DR VARIDH
Assistant Surgeon 2nd : DR MANMATH
D.O.ADM.: FEB 6, 2022 OPERATION : FEB 6, 2022 OPERATION 2: FEB 10, 2022 OPERATION
3: FEB 17, 2022 OPERATION 4: MAR 2, 2022 DIS.: MAR 18, 2022

Diagnosis : MEDULLOBLASTOMA S/P LEFT-MPVP SHUNT
BIOPSY: MEDULLOBLASTOMA, WNT ACTIVATED

Presenting complaints: PT WAS APPARENTLY WELL TILL 1 YEAR BACK WHEN SHE DEVELOPED HEADACHE, HOLOCANIAL, MILD, INITIALLY NOT ASSOCIATED WITH VOMITING, RELIEVED ON MEDICATION. C/O EXACERBATION OF HEADACHE SINCE 3 MONTHS. C/O VOMITING SINCE 2 MONTHS, NON BILIOUS, NON PROJECTILE, MULTIPLE EPISODES PER DAY, NO RELIEF IN HEADACHE POST VOMITING. C/O GENERALISED WEAKNESS SINCE 2 MONTHS. C/O BLURRING OD VISION SINCE 2 MONTHS, GRADUALLY PROGRESSIVE,, PAINLESS C/O 2 EPISODES OF TONIC POSTURING OF BODY - 2 EPISODES ; 1.5 MONTHS BACK, 3 DAYS BACK NO H/O FEVER, WEAKNESS, SEIZURES, DIMINUTION OF VISION

Past history :
NO H/O DM, TB, HTN, ASTHMA, THYROID DISORDERS

Examination Findings:
PATIENT IS ALERT CONSCIOUS, E4V5M6
CRANIAL NERVES -
VA - B/L HMCV, NO FIELD CUTS
PUPILS - B/L NSRL
OTHER CN WNL
MOTOR - B/L TONE AND BULK EQUAL IN UL, LL
POWER 5/5 IN B/L UPPER AND LOWER LIMBS
DTR 2+ IN B/L AJ/KJ/BJ/TJ/SJ
NO SENSORY DEFICITS
NO CEREBELLAR SIGNS

Investigation

PRE-OP

POST-OP

** THIS NOTE CONTINUED ON NEXT PAGE **

KUMARI, ANUSHKA
105-79-5024 DOB: 02/05/2013

AIIMS NEW DELHI
Pt Loc: OUTPATIENT

Printed: 03/18/2022 12:07
Vice SF 509

MEDICAL RECORD

03/18/2022 11:36 ** CONTINUED FROM PREVIOUS PAGE **

HEMATOLOGY :		28/2/22	1/3/22
HGB :		12.7	10
PLATELETS :		224	200
TLC :		8250	10900
BIOCHEMISTRY	REF. RANGE	PRE-OP	POST-OP
UREA :	(10-50)mg%	20	16
CREATININE :	(0.5-1.8)mg%	0.4	0.6
SODIUM :	(130-149)mEq/L	140	137
POTASIUM :	(3.5-5.0)mEq/L	4	4.2
COAGULATION PROFILE		PRE-OP	POST-OP
INR		1.2	1.1

SARS CORONAVIRUS- 2 (Real time RT-PCR):3/2/22: Negative for SARS Coronavirus-2
 X-RAY CHEST:WNL, ECG :WNL, URINE RM : WNL
 CEMRI Brain(28/1/2022)- 3*3CM HYPOT1 HYPERT2 CONTRAST ENHANCING LESION IN 4TH
 VENTRICLE WITH HYDROCEPHALUS S/O POSTERIOR FOSSA SOL
 POST OP NCCT HEAD (10/2/22): MILD IVH, NO HYDROCEPHALUS
 HPE REPORT : RECEIVED TWO SPECIMENS SPECIMEN 1. DURAL BIOPSY: RECEIVED TWO SOFT
 TISSUE PIECES TOGETHER MEASURING 1X0.4X0.3CM. SPECIMEN 2. TUMOR TISSUE: RECEIVED
 MULTIPLE SOFT TISSUE PIECES TOGETHER MEASURING 3X1.5X0.8CM. MICROSCOPY: SECTIONS
 EXAMINED FROM BOTH THE SPECIMENS SHOW HISTOMORPHOLOGICAL FEATURES OF CLASSIC
 MEDULLOBLASTOMA. THE TUMOR CELLS ARE IMMUNOPOSITIVE FOR SYNAPTOPHYSIN. MIB-1
 LABELING INDEX IS APPROXIMATELY 10%. MOLECULAR PROFILE OF THE TUMOR IS AS
 FOLLOWS: YAP- NEGATIVE GAB- NEGATIVE BETA CATENIN- POSITIVE (NUCLEAR) P53-
 NEGATIVE IMPRESSION: MEDULLOBLASTOMA, WNT- ACTIVATED.

Therapeutic Procedure

Surgeon :DR RS/DR SIVASAI Operation-1:FEB 6,2022

OPERATIVE PROCEDURE: RIGHT MPVP SHUNT

OPERATIVE FINDINGS: RIGHT OCCIPITAL BURR HOLE MADE, VENTRICLES HIT IN 1S
 ATTEMPT, CSF UNDER HIGH PRESSURE. ABDOMINAL END PLACED IN PERITONEAL CAVITY AND
 CONNECTED.

Surgeon :DR SK/DR SUNDAR/DR HEMANTH Operation-1:FEB 10,2022

OPERATIVE PROCEDURE: MLSOC + GTE OF MEDULLOBLASTOMA

OPERATIVE FINDINGS: MLSOC DONE AND C1 ARCH REMOVED. Y SHAPED DUROTOMY DONE.

BRAIN TENSE AND BULGE

PRESENT ON OPENING. TRNSVERMIAN APPROACH TAKEN. TUMOR WAS GREYISH WHITE, SOFT,
 MODERATELY VASCULAR, CUSA SUCKABLE. TUMOR WAS SEEN TO BE ARISING FROM MEDULLARY
 VELUM, S/O MEDULLOBLASTOMA. GROSS TOTAL EXCISION OF TUMOR DONE

Surgeon :DR SK/DR ARUNNATH Operation-1:FEB 17,2022

OPERATIVE PROCEDURE: LEFT FRONTAL OMMAYA INSERTION AND RIGHT FRONTAL EVD REMOVAL

OPERATIVE FINDINGS: VENTRICLES HIT IN 1ST ATTEMPT, BLOOD TINGED CSF AT MODERATE
 PRESSURE EGRESSED. LEFT FRONTAL OMMAYA INSERTED AND RIGHT FRONTAL EVD REMOVED

Surgeon :DR PRAHLAD (ENT) Operation-1:FEB 21,2022

OPERATIVE PROCEDURE: OPEN TRACHEOSTOMY

OPERATIVE FINDINGS: OPEN TRACHEOSTOMY DONE UNDER GA, 5.5MM CUFFED TUBE INSERTED,
 CONFIRMED BY ETCO2 AND B/L CHEST EXPANSION

** THIS NOTE CONTINUED ON NEXT PAGE **

KUMARI, ANUSHKA
 105-79-5024 DOB:02/05/2013AIIMS NEW DELHI
 Pt Loc: OUTPATIENTPrinted:03/18/2022 12:07
 Vice SF 509

MEDICAL RECORD

Progress Notes

03/18/2022 11:36

** CONTINUED FROM PREVIOUS PAGE **

Surgeon : DR SL/DR ARUNNATH Operation-1: MARCH 2, 2022
OPERATIVE PROCEDURE: LEFT MPVP SHUNT AND REMOVAL OF RIGHT FRONTAL OMMAYA
OPERATIVE FINDINGS: LEFT OCCIPITAL BURR HOLE MADE, VENTRICLES HIT IN 1S
ATTEMPT, CSF UNDER HIGH PRESSURE. ABDOMINAL END PLACED IN PERITONEAL CAVITY AND
CONNECTED.

Course in Hospital

PATIENT UNDERWENT VP SHUNT ON EMERGENCY BASIS AFTER ADMISSION F/B PRIMARY
SURGERY OF GTE OF POSTERIOR FOSSA SOL. POST OP PATIENT WAS SHIFTED, INTUBATED.
TO ICU, GCS WAS E4VTM6 AFTER REVERSAL. ON POD3 (12/2/22) PATIENT GCS
DETERIORATED TO E4VTM5 AND RIGHT FRONTAL EVD WAS INSERTED IN ICU. ON 17/2/22
LEFT FRONTAL OMMAYA WAS INSERTED AND RIGHT FRONTAL EVD WAS REMOVED, PATIENT WAS
EXTUBATED POST OP. POST OP CT WAS S/O MILD IVH, OMMAYA WAS IN SITU. PATIENT WAS
REINTUBATED ON 19/2/22 DUE TO POOLING OF SECRETIONS AND DROWSY STATUS
OBSERVED. PATIENT UNDERWENT TRACHEOSTOMY BY ENT ON 21/2/22. PATIENT UNDERWENT
LEFT MPVP SHUNT AND REMOVAL OF RIGHT FRONTAL OMMAYA INSERTION ON MARCH 2, 2022.
ON REVERSAL PT GCS WAS E4VTRM5. PATIENT DEVELOPED UTI WHICH WAS MANAGED ON
ANTIBIOTICS. PATIENT WAS WEANED OFF VENTILATOR AND IS BEING DISCHARGED ON ROOM
AIR.

Others :

Condition On Discharge: Afebrile, GCS E4VTRM5, VITALS STABLE, NEUROLOGICALLY SAME
AS PRE OP. WOUND HEALTHY

Comments:

PATIENT NEEDS REGULAR FOLLOW UP IN NEUROSURGERY OPD.

Advice On Discharge

TAB PCM 500MG TDS FOR 5 DAYS 0-0-0
SYP POLYBION 2TSP BD FOR 2 MONTHS
TAB PANTOP 20MG OD FOR 5 DAYS -1/2-0-0 25th मई
TAB EPTOIN 50MG TDS TO CONTINUE
SYP CREMAFFIN 6TSP HS FOR 5 DAYS
FOLLOW UP IN NSX OPD ON 25TH MARCH, 2022
CHEST PHYSIOTHERAPY
LIMB PHYSIOTHERAPY
TRACHEOSTOMY TUBE CARE
TO GET CEMRI BRAIN AFTER 3 MONTHS
Follow up Appointment

> COLLECT BIOPSY REPORT FROM ROOM NO. 720, 7th FLOOR, C.N.CENTRE AFTER 10 DAYS
> FOLLOW UP IN NEURO SURGERY OPD OF UNIT-2 ON TUE AT 8:30AM TO 10:30AM OR
FRIDAY AT 8:30AM TO 10:30AM UNDER DR SHWETA KEDIA
PREPARED BY : DR SUNDAR/DR. HEMANTH
PLEASE LAMINATE THIS DOCUMENT PLEASE MAKE 2 PHOTOCOPIES
PLEASE SAVE THE UHID NUMBER AS IT IS ESSENTIAL TRACK ALL THE DIGITAL RECORDS
FOR APPOINTMENT CONTACT -011 -26594656, CNC OPD, CENTER NO.33.

End of note

** THIS NOTE CONTINUED ON NEXT PAGE **

KUMARI, ANUSHKA
105-79-5024 DOB: 02/05/2013

AIIMS NEW DELHI
Pt Loc: OUTPATIENT

Printed: 03/18/2022 12:07
Vice SF 509

MEDICAL RECORD

Progress Notes

NOTE DATED: 02/12/2022 23:23

LOCAL TITLE: NEUROSURGERY OPERATION NOTE

STANDARD TITLE: NEUROLOGICAL SURGERY NOTE

VISIT: 02/12/2022 23:23 DR OFFICE

DEPARTMENT OF NEUROSURGERY
CARDIO NEURO SCIENCES CENTRE
AIIMS, NEW DELHI-110029

OPERATION NOTE

NOTE-Unless otherwise specified all dates mentioned in this note are in the formate MM/DD/YYYY

UHID NO:105-79-5024

OPERATION NOTE NO.:2

PATIENTS NAME: KUMARI, ANUSHKA AGE:9 Yrs SEX:FEMALE
WARD:NS-2 BED NO:15
OP DATE:Feb 10,2022 OT:6

MARITAL STATUS:MARRIED SERVICE:
ANAESTHETIST: PROF CHAUHAN/DR JAYANT
ANAESTHESIA:GA
SURGEON:DR SHWETA KEDIA

ASSISSTANT SURGEON 1st:DR SUNDAR
ASSISSTANT SURGEON 2nd:DR HEMANTH

PRE OPERATIVE DIAGNOSIS: MEDULLOBLASTOMA

POST OPRATIVE DIAGNOSIS: MEDULLOBLASTOMA

OPERATIVE PROCEDURE PROPOSED: MLSOC + GTE OF MEDULLOBLASTOMA

OPERATIVE PROCEDURE EXECUTED: MLSOC + GTE OF MEDULLOBLASTOMA

SKIN PREPARATION:SOAP, ETHER, BETADINE

INTRA OP ANTIBIOTICS:
INJ.CEFOTAXIME1GM
INJ.AMIKACIN500MG

SPECIAL EQUIPMENT REQUIREMENT :MICROSCOPE

MATERIAL SENT TO HISTOPATHOLOGY: TUMOR TISSUE

I/O FLUIDS:

** THIS NOTE CONTINUED ON NEXT PAGE **

KUMARI, ANUSHKA
105-79-5024 DOB:02/05/2013

AIIMS NEW DELHI
Pt Loc: OUTPATIENT

Printed:03/18/2022 09:48
Vice SF 509

MEDICAL RECORD

02/12/2022 23:23

** CONTINUED FROM PREVIOUS PAGE **

Progress Notes

URINE OUTPUT:700ml
IV fluid :1500ml
BLOOD LOSS :900ml

COLLECTIONS:

FFP :2
PRP :2
RBC :3
INDUCTION TIME :9:30AM
INCISION TIME :11AM
CLOSURE TIME :7:30PM

OPERATIVE FINDINGS:

MLSOC DONE AND C1 ARCH REMOVED. Y SHAPED DUROTOMY DONE. BRAIN TENSE AND BULGE PRESENT ON OPENING. TRNSVERMIAN APPROACH TAKEN. TUMOR WAS GREYISH WHITE, SOFT, MODERATELY VASCULAR, CUSA SUCKABLE. TUMOR WAS SEEN TO BE ARISING FROM MEDULLARY VELUM, S/O MEDULLOBLASTOMA. GROSS TOTAL EXCISION OF TUMOR DONE

INCISION:INION TO C2
SURGICAL POSITION:PRONE, HEAD FIXED IN 3 PIN

OPERATIVE PROCEDURE
UNDER GA, PATIENT POSITIONED SUPINE, LINEAR INCISION GIVEN FROM INION TO C2. MLSOC DONE AND C1 ARCH REMOVED. Y SHAPED DUROTOMY DONE. BRAIN TENSE AND BULGE PRESENT ON OPENING. TRNSVERMIAN APPROACH TAKEN. TUMOR WAS GREYISH WHITE, SOFT, MODERATELY VASCULAR, CUSA SUCKABLE. TUMOR WAS SEEN TO BE ARISING FROM MEDULLARY VELUM, S/O MEDULLOBLASTOMA. GROSS TOTAL EXCISION OF TUMOR DONE. DURA CLOSED WATERTIGHT IN PRIMARY FASHION. WOUND CLOSED IN LAYERS OVER DRAIN.

DRAFT COPY - DRAFT COPY -- ABOVE NOTE IS UNSIGNED-- DRAFT COPY - DRAFT COPY

KUMARI, ANUSHKA
105-79-5024 DOB:02/05/2013

AIIMS NEW DELHI
Pt Loc: OUTPATIENT

Printed:03/18/2022 09:48
Vice SF 509



भारत सरकार

Government of India



कु. अनुष्का

Km. Anushka

पिता : विकास कुमार

Father : Vikas Kumar

जन्म तिथि / DOB : 04/05/2012

महिला / Female



9554 3306 1328

आधार - आम आदमी का अधिकार



भारतीय विशिष्ट पहचान प्राधिकरण

Unique Identification Authority of India

पता:

आत्मजा: विकास कुमार, नगला पोता,
एटा, एटा, उत्तर प्रदेश, 207001

Address:

D/O: Vikas Kumar, Nagla Pota,
Etah, Etah, Uttar Pradesh, 207001

9554 3306 1328



1947

1800 300 1947



help@uidai.gov.in

WWW

www.uidai.gov.in



भारत सरकार

Government of India



सोनी

Soni

जन्म तिथि / DOB : 03/03/1991

महिला / Female



8964 0470 5051

आधार - आम आदमी का अधिकार



भारतीय विशिष्ट पहचान प्राधिकरण

Unique Identification Authority of India

पता:
संबोधित: विकास कुमार, 665 नगला
पोता, एटा, एटा, एटा, उत्तर प्रदेश,
207001

Address:
W/O: Vikas Kumar, 665 NAGLA
POTA, ETAH, Etah, Etah, Uttar
Pradesh, 207001

8964 0470 5051



1947
1800 300 1947



help@uidai.gov.in

WWW

www.uidai.gov.in