

TIME: 9:05 AM

10:00 AM

26/09/21



अ० भा० आ० सं० अस्पताल / A.I.I.M.S. HOSPITAL बहिरंग रोगी विभाग / Out Patient Department



एकक/Unit _____
विभाग/Dept. _____
नाम/Name _____

Dept Reg. 2021/062/0003008
New Patient
General/W O
Room/Room: 11
Dept: _____
Name, Mr. AASHVIK
KUMAR
Gender No: M
27 AN 90 YRS/M
PR: 9106140308
LNED: 105477/55
Date: 11/09/2021

OPR-6

Ign. No. _____
पता/Address _____

निदान/Diagnosis

GDD & epilepsy

उपचार/Treatment

दिनांक/Date
T = 36.8°C
No 8/8
no contact
attendant
T = 36.5°C

clo delay in attainment of milestones...
h/o new admission - (A)
h/o seizures - frequent

MR I
Squela of
Perina had hypoxic
ischemic insult
multifocal
cystic
encephalomalacia

cm: Partial rec holding
fm: Palmar grasp
Longue: Coog
labialling
Soeal: Does not
recognise mother
No eye contact

grc
UL
- Bulk (A)
- Tone ↑ in ble elbow flexion;
supination, & 1+ (MAS)
- PROM - full
massy
LL
- Bulk (A)
- Tone ↑ in ble knee extension
ankle DF (mas 1+).
- Actively moving all 4 limbs.

OR/673/21
Prakash chandera



CLEAN AND GREEN AIIMS / एम का घरी संकल्प, स्वच्छता से काय कल्प
अंगदान-जीवन का बहुमूल्य उपहार / ORGAN DONATION - A GIFT OF LIFE
O.R.B.O., AIIMS, 26588360, 26593444, www.orbo.org Helpline - 1060 (24 hrs service)



Adv


- ① Activities to improve neck holding
- ② CP chair
- ③ Activities to improve trunk balance, hand function
- ④ Sustained stretching of bicep elbow extensors
wrist flexors, knee extensors, ankle dorsiflexors,
peroneus longus, brevis
- ⑤ Corner sitting
- 6/7 ⑥ Occupational Speech therapy - ENT.
- ⑦ Early stimulation
- ⑧ Neurodevelopmental therapy
- ⑨ Play therapy
- ⑩ BL KAFO & high lat trimline as night splint
- ⑪ Activities to inhibit ATWR
- ⑫ R/w after 3 months

13/8/21

C.T

Exb. obsv.

RKS
13/8/21


Dr Akhil Jethi
JR / PMR

Senior Registrar
Department of Physical Medicine & Rehabilitation
All India Institute of Physical Disabilities
New Delhi



ओ भा० आ० सं० अस्पताल / A.I.I.M.S. HOSPITAL
वहिरंग रोगी विभाग / Out Patient Department

अस्पताल के अन्दर धूम्रपान करना है। / SMOKING IS PROHIBITED IN HOSPITAL PREMISES



OPR-6

एकक/Unit

II

विभाग/Dept. PEDIATRIC

रोगी/पंजीकृत सं०/O.P.D. Regn. No. 105477755

नाम/Name	पिता/पुत्र/पत्नी/पुत्री F/S/W/D of	लिंग Sex	वय Age	पता/Address
Aashvik Kumar	Kaushal Kishore	M	2 years	Gaya, Bihar (P.O.)

निदान/Diagnosis

GDD = Epilepsy & evaluation (? Infantile spasms)

~~Infantile spasms~~
उपचार/Treatment ? Structural West Syndrome

दिनांक/Date
13/07/2021
व्य - P. S. G.

c/o global developmental delay noted since 3-4 months of age

c/o spasms since 6 months of age
Around 4-5 single spasms/day.

→ Dev h/o: Neck holding (+)
No visual fixation & following
Startle response to sound (+)

o/e Spasticity (+) Microcephaly (+)
Brisk reflexes (+)
Plantar-Extensor.

Bisph h/o's
Tet / LSCS
C.B.
H/o SVT (+)

MF Brain. (Repeat)
Films - NA
S/o multicyclic encephalomalacia

Adv.

1) Syp. VALPROATE (5ml/200mg)
2.5ml — 2.5ml — 2.5ml

2) Tab. CLONAZEPAM (0.25 mg)
X ————— 1

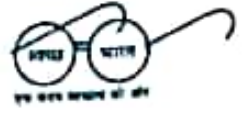

CLEAN AND GREEN AIIMS / एम का दही संकल्प, स्वच्छता से काया कल्प
अंगदान-जीवन का बहुमूल्य उपहार / ORGAN DONATION - A GIFT OF LIFE
O.R.B.O., AIIMS, 26588360, 26593444, www.orbo.org Helpline - 1060 (24 hrs service)





अ० भा० आ० सं० अस्पताल / A.I.I.M.S. HOSPITAL
बहिरंग रोगी विभाग / Out Patient Department



अस्पताल को अन्दर धूम्रपान मना है। / SMOKING IS PROHIBITED IN HOSPITAL PREMISES

शरीरमात्रं खलु वर्मसाधनम्

OPR-6

एकक/Unit _____
विभाग/Dept. _____

नाम/Name _____

राज्यिक पहचान



UHID 105477755
Dist No. 20210090003601
Clinic No.

रूम / Room

A-138

Psy-Unit

Psychiatry

Queue No. N2

12/07/2021

AASHVIK KUMAR
2Y / M पुरुष
SOKALSHAL KSHOR

सोम, मंगल, बुध, गुरु, शुक्र, शनि
MON, TUE, WED, THU, FRI, SAT

ADD VLL-TITAGAN, POST OFFICE,
TEHAR PIN CODE - 824239 DISTRICT -
DAYA BHAR PIN 824239 JGA
Mob: 9106182128 New Patient Charge: ₹ 10 Reporting: 10:00
AM-10:30 AM



n. No. _____

पता/Address _____

निदान/Diagnosis

दिनांक/Date

उपचार/Treatment

W/O HIE
MRI - sequelae of
perinatal hypoxia -
ischemic insult +
multifocal cystic
encephalomalacia.

Refer to Paediatric
medicine / Paeds.
Neurology.



Dr. ABHISHEK CHAKRADAR
M.B.B.S., M.D. (PSYCHIATRY)
SENIOR RESIDENT
DEPT. OF PSYCHIATRY
A.I.I.M.S. NEW DELHI
DMC REG- 92239

शरीरमात्रं खलु वर्मसाधनम्



CLEAN AND GREEN AIIMS / एम्स का यही संकल्प, स्वच्छता से काया कल्प
अंगदान-जीवन का बहुमूल्य उपहार / ORGAN DONATION - A GIFT OF LIFE
O.R.B.O., AIIMS, 26588360, 26593444, www.orbo.org Helpline - 1060 (24 hrs service)



films.

AIIMS U	117755
IC NO	11
Report to	DR. K. KUM
Address	13-07-11
Date	Free Discharge
Type	SUPERVISOR
Specialist	PAEDIATRICS
Specialty	
Center Name	
Batch	
Lot No	1005MG TABLET
Lot No	1193722
EXP. DATE	
Lot No	21187-285
Lot No	2
Lot No	142

- 3) Tab. TIZANIDINE (2mg)
1/2 ——— 1/2 ——— x
- 4) Tab. PACITANE (2mg)
1/2 ——— 1/2 ——— x
- 5) Ophthalmological evaluation (RAC)
- 6) Hearing assessment / BERA - ENT OPD.
- 7) PMR (OT/PT)
- 8) To R/A 3 months.

[Signature]
 (Dr. Gauzam)
 Deputy Director
 All India Institute of Medical Sciences
 Anand Nagar, New Delhi-110029

Generic Drug Store
 Managed by MCL Lifecare Ltd.

Received By:

Received Date: 13/07/23 / 3.57

Verified By:



अ० भा० आ० रा० अस्पताल / A.I.I.M.S. HOSPITAL
बहिरंग रोगी विभाग / Out Patient Department



आवृत्ति के बिना दवाएं नहीं दी जाती / DRUGS IS PROVIDED IN HOSPITAL PREMISES

GPR-6

दिनांक / Date
विभाग / Dept

PEDIATRICS

रजिस्ट्रेशन नंबर / Reg No: 1054777-25

नाम / Name	पिता/माता/पति/पत्नी F/S/W/D of	लिंग Sex	वय Age	पता / Address
Aashvik Kumar	Kaushal Kishore	M	2 years	Gaya, Bihar (P-01)

रिपोर्ट / Diagnosis

GDD ± Epilepsy & evaluation (? Infantile Spasms)
~~Infantile Spasms~~

दिनांक / Date

3/03/2021
W4 - P. 8kg

उपचार / Treatment

? Structural West Syndrome

c/o global developmental delay noted since 3-4 months of age
c/o spasms since 6 months of age
Around 4-5 single spasms/day.

→ Dev h/o: Neck holding ⊕
No visual fixation & following
Startle response to sound ⊕

o/e Spasticity ⊕ Microcephaly ⊕
Risk WTR ⊕
Plantar Extensor.

Adv.

- Syp. VALPROATE (5ml/200mg)
2.5ml — 2.5ml — 2.5ml
- Tab. CLONAZEPAM (0.25 mg)
x ————— 1

Risk h/o's
Term / WGS / B-W 3kg
CIAB
H/o NNT ⊕

MRI Brain. (Repeat)
films - NA
s/o multicystic encephalomalacia



CLEAN AND GREEN AIIMS / एम्स का वहीं संकल्प, स्वच्छता से बनाया कल्प
अंगदान-जीवन का बहुमूल्य उपहार / ORGAN DONATION - A GIFT OF LIFE
O.R.B.O., AIIMS, 26588360, 26593444, www.orbo.org Helpline - 1060 (24 hrs service)



477755
 30199 TOKEN NO. 707
 Name: AASHOK KUMAR
 13.07.21 to 27.11
 Free Institution
 Unit: SUPERVISION
 Wg: PAEDIATRICS
 Name: _____
 Batch: _____ Exp: _____
 AZEPAM 0.5MG TABLET
 MT163792 01-22
 EXYPHENOL HYDRATE RID
 21JPT.089
 Item: 2
 Qty: 140

1/mv3

- 3) Tab. TIZANIDINE (2 mg)
 $\frac{1}{2}$ ——— $\frac{1}{2}$
- 4) TAB. PACITANE (2 mg)
 $\frac{1}{2}$ ——— $\frac{1}{2}$
- 5) Ophthalmological evaluation / RI
- 6) Hearing assessment / BERA
- 7) PMR (OT/PT)
- 8) To R/A 3 months.

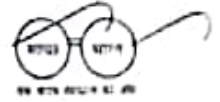
 COE. 6/21

1. All drugs to be stored in the
 2. All drugs to be stored in the
 3. All drugs to be stored in the

Generic Drug Store
 Managed by HCL Infosys Ltd.
 Received Date: 13/07/21 / 3.17
 Verified by:



अ० भा० आ० सं० अस्पताल / A.I.I.M.S. HOSPITAL
बहिरंग रोगी विभाग / Out Patient Department



अस्पताल में धूम्रपान करना मना है / SMOKING IS PROHIBITED IN HOSPITAL PREMISES

रोगी का नाम / Name
पता / Address

आरोग्य केंद्र / Center
1100477255
Dept No. 202100003001
Chhtr. No.

रोगी का कमरा / Room No.
A-136
Psy. Lab
Psychiatry
Queue No. 102
12/07/2021

OPR-6

रोगी का पता / Address

AASIVIK KEIMAN
ZY (M) (M)
SUKAJSMAL KIDMUN
Add: VILL. TAGAN, POST OFFICE,
TEHAR, PIN CODE - 124236 DISTRICT,
GANA BHAR, PIN 124236, INDIA
Mob: 9126162108 New Patient General Fee 10 Reporting 10:00 AM-12:30 AM

रोगी का समय / Time
MON, TUE, WED, THU, FRI, SAT



निदान / Diagnosis

दिनांक / Date

उपचार / Treatment

14/10 HIE

MRI - sequelae of perinatal hypoxia - ischaemic insult + multifocal cystic encephalomalacia.

Ref to Paediatric medicine / Paeds.

Neurology.

Signature



DR. ABHISHEK CHAUDHARI
M.B.B.S., M.D. (PSYCHIATRY)
SENIOR RESIDENT
DEPT. OF PSYCHIATRY
A.I.I.M.S. NEW DELHI
DMC REG- 92239

परमार्थं सतु धर्मस्य वरुण



CLEAN AND GREEN AIIMS / एम्स का यही संकल्प, स्वच्छता से काया कल्प
अंगदान-जीवन का बहुमूल्य उपहार / ORGAN DONATION - A GIFT OF LIFE
O.R.B.O., AIIMS, 26588360, 26593444, www.orbo.org Helpline - 1060 (24 hrs service)



Date: 20-Sep-2019

PATIENT INFORMATION

ID : 637
Name : Ashvik Kumar
Age : 06 Months (M)
Address : Gaya
Handedness : Right
Medication :
Last Attack :
Refd. By : Dr. Sanjay Kumar MD, DM

NOTES

This resting record is characterised by the background activity of 4-5Hz upto 30 microvolts alpha rhythm over both posterior regions bilaterally which is reactive to eye opening & close.

Patient developed intermittent or w/d attacks marked by vertex sharp waves.

Multi focal interictal epileptiform discharge seen without any secondary generalization.

IMPRESSION:- Abnormal sleep EEG

Please correlate clinically.

PARAMHANS INSTITUTE OF NEUROLOGY

Rd.No-2,L.P.Shahi House,South of Power House, Rajendra Nagar,Patna-16
Phone :- 0612-2666667,9693212995 Mob-09304508599



PATIENT INFORMATION

Date: 20-Sep-2019

ID: 045
Name: Ashvik Kumar
Age: 0 Yrs 6 Mths Male
Ht/Wt: 0 cms/0 Kgs
Refd. By: Dr.Sanjay Kumar, MD,DM.
Technician:
Diagnosis:

BAER

The Pt. was relaxed during the test .The skin impedance was fully under normal limit .The test was done on difference intensity levels to determine the thresholds and to study the BAER finding a total of 2000 stimulus was used .

The V peak which determines threshold of hearing is present at 30dB i.e minimum level at which peak V is present in both ears . All the three important peaks I,III,V have occurred .The interpeak latency time is as follows :-

	I-III (mS)	III - V (mS)
Rt.	1.83	1.58
Lt.	1.67	1.78

IMPRESSION :- This BAER study is within normal limit.

Please correlate clinically.


DR. SANJAY KUMAR MD. DM.



Centre of Excellence in Diagnostic Care
AN ISO 9001 : 2015 CERTIFIED CENTRE

Dev Imaging & Diagnostic Centre

(A Unit of Dev Institute of Nuclear Medicine Pvt. Ltd.)

D5 24/B, Digamber Place, Behind Lohia Nagar Petrol Pump, Kankarbagh, Patna - 800 020
Phones : 07544008111, 07544008112 E-mail : devnuclear_inst@rediffmail.com

NAME: ASHVIK KUMAR **06 MONTHS / F**
REF BY DR : SANJAY KUMAR , MD,DM (Neuro)
EXAMINATION: BRAIN 20-09-19

=====

THANKS FOR THE REFERRAL

MRI BRAIN (PLAIN)

TECHNIQUE: On a SIEMENS ESSENZA 1.5 T magnet , the following pulse sequences were obtained- Axial-T1 FLAIR , T2W, FLAIR, GRE, Coronal -T2W sag—T2W

FINDINGS:

On T2W images ill defined hyperintensity are seen in parieto-occipital and adjacent frontal region bilaterally involving both cortex and subcortical White matter , Widening of cortical sulci are seen. Few cystic changes are also seen .They appear hypointense on T1W images .

Paucity of white matter is also seen in posterior periventricular region bilaterally. Widened subarachnoid space is seen bilaterally. Anterior interhemispheric fissure is also widened

No evidence of hemoglobin degradation product is seen on GRE images.

No evidence of restricted diffusion is seen on DW images.

Both lateral and third ventricles are dilated .There is no mid line shift.

Brainstem, cerebellum, C.P. angle cistem and fourth ventricle are normal.

Major intracranial vessels reveal normal signal void on spin echo images. Visualized orbits are unremarkable.

IMPRESSION

- Above findings are consistent with sequelae of perinatal hypoxic - ischemic insult with multifocal cystic encephalomalacia, .

DR RAVI SHANKAR KUMAR , MD.



परमहंस इन्स्टीच्युट ऑफ न्यूरोलॉजी

डॉ. संजय कुमार

एम्स अम्स प्रोफेसर ऑफ न्यूरोलॉजी आई.बी.आई.एम.एस.
कन्सल्टेंट न्यूरोलॉजिस्ट, पी.एम.सी.एच., पटना

समय : सोमवार से शुक्रवार
2.00 P.M. to 09.00 P.M.

रविवार बंद

PATIENT'S CLINICAL DETAILS

Name Ashnik Kumar Age 6 months Sex Male Weight 7.48
Ref. By Address Litany Date 19/09/19

बच्चा का जन्म ओपेन में हुआ था, जन्म के समय बच्चा रोया था, बच्चा को जन्म से ही जींदा था,
अभी बच्चा का उम्र 6 months है
जन्म से बच्चा का पूरा शरीर में, कम्पन होता था
लान्का 2 महिना से आँख ऊपर निचे करने लगा है दोनों हाथ-पैर टाइट कर मेंता है और स्थिर हो जाता है
जो कान से ज्यादा कर रहा है

PHYSICAL EXAMINATION

P I LN Cyan
Oed Thyroid Clubbing
Pulse Rate : 88 BP :
CVS : S1 S2 M3 Tobacco :
Chest Abdomen
BN L S AST
HMF :
CN I/II-Pupil: LR TAR
III/IV/VI-EOM: P S C
Fundus :
VII :
VIII :
IX/X/XI/XII:

Motor UL LL
Bulk :
Tone :
Power UL LL

RT	P <u>5</u>	P <u>5</u>
	D <u>5</u>	D <u>5</u>
LT	P <u>5</u>	P <u>5</u>
	D <u>5</u>	D <u>5</u>

DTR BJ SJ TJ KJ AJ
RT
LT

Plantar RT LT
Senson I/PS :
Pain/Temp :
Romberg's :
Gait :
Coordination :
Neck Rigidity :
Peripheral Nerve :

EPS : Tremor | Rigeity | Freezing | Bradykinisia
Postural Instability | Flexed Posturing

PERSONAL HISTORY

Alcohol :
Smoking :
Tobacco :

TREATMENT HISTORY

TEST ALREADY DONE

PAST HISTORY

BT : Jaund Allergy
HTN : DM : Thyroid
BPH : CAD : COPD :
OCP :

FAMILY HISTORY

PROVISIONAL DIAGNOSIS

DSD



Dr. Sanjay Kumar

MBBS (Hons); MD (MEDICINE)
D.M. (Neurology), IPGMER, Kolkata
Ex. Asst. Professor of Neurology IGIMS
Associate Professor of Neurology, PMCH Patna.

Time : Monday to Friday
2 P.M. - 7 P.M.
Ph: 0612-2666667
Mob.: 9693212995
9304508599
Mail : pinpat0111@gmail.com

Date 19-09-19

DIHESD

Ashvik Kumar
6 months / (M)
Gaya

Acty

- ① MRI Brain (Epileptic Profile)
↳ (IHEZ Multifocal cystic encephalomalacia)
- ② EEG / VEP / BAC R
- ③ TSH / CBC /

Rx

- ① Symp. Gardinal
1.5ml ————— 2.5ml = to let
- ② Symp Nuzet
2ml ————— 2ml = to let
- ③ Symp Stelcal
x ————— 2ml = to let

Recur after 2 months

17-09-2019

6.5 kg.

Rx

- ① Symp Gardinal
2.5ml ————— 2.5ml = to let
- ② Symp Nuzet
x 2ml ————— 2ml = to let
- ③ Symp Stelcal
x ————— 2ml = to let

AS

- ① G. Gardinal
3ml ————— 3ml 2
- ② G. Nuzet
2.5ml ————— 2.5ml

Avoid Quinolones

- ⇒ Ciprofloxacin
- ⇒ Ofloxacin
- ⇒ Moxifloxacin etc

Recur after 3 months

16 JUN 2020

8 kg

97°F

Road No.-2, House of L.P. Shahi, South of Power House, Rajendra Nagar, Patna-800016

15 दिन बाद पुनः फीस लगेगा। Not For Medico Legal Purpose

दया खाने के दौरान किसी तरह की असुविधा होने पर स्थानीय चिकित्सक से संपर्क करें।

