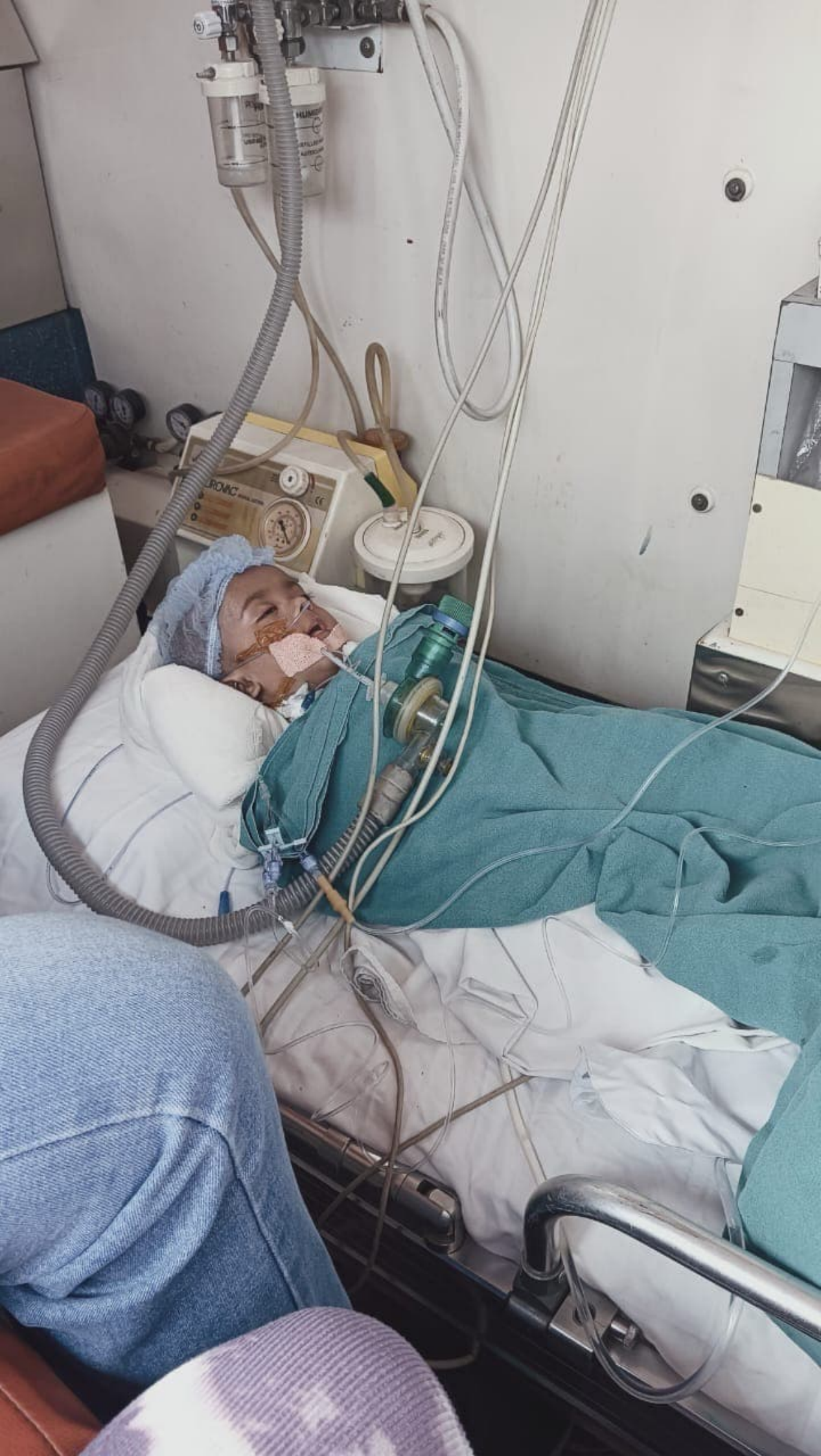





Embrace Good Health

AMRITA INSTITUTE OF MEDICAL SCIENCES & RESEARCH CENTRE  
PAN NO: AAATM2403M , Appointment call: 01292851234  
Mata Amritanandamayi Marg, Sector 88, Faridabad, Haryana 121002

|                                    |  |                           |                               |
|------------------------------------|--|---------------------------|-------------------------------|
| <b>MRD No:</b> 136723              | <b>Gender:</b> Female                    | <b>DOB:</b> 29/12/2023    | <b>Age:</b> 7M 8D             |
| <b>Name:</b> HEZAL SONI            | <b>Visit Type:</b> OP                    | <b>Visit Code:</b> OP0003 | <b>Visit Date:</b> 01/08/2024 |
| <b>Consultant:</b> Dr. Sushil Azad | <b>Speciality:</b> Paediatric Cardiology |                           |                               |

### ECHO PEDIATRICS

Study Date: 01/08/2024

#### History:

Post infectious (post Ventriculitis) Hydrocephalus

#### Interpretation Summary:

Situs solitus, levocardia, d loop. Normal segmental analysis. PFO (Left to right shunt). Intact IVS. Laminal inflow and outflows. Trace TR (peak PG= 18 mmHg). Tricuspid aortic valve. Normal coronaries. Confluent and adequate branch PA's. Left arch. Normal branching. No CoA. No PDA. No LSVC. Normal biventricular function.

#### Cardiac Position

Levocardia  
Abdominal Situs solitus  
Atrial situs solitus  
D ventricular Loop  
Normal position great vessels

#### Vein

Normal systemic venous drainage  
Normal pulmonary venous drainage.

#### Atrium

Normal right atrial size  
Normal left atrial size  
Patent foramen ovale

#### Atrioventricular Valves

Normal tricuspid valve  
Normal mitral valve

#### Ventricles

Normal left ventricular structure and size  
Normal right ventricular structure and size  
Intact ventricular septum

AMRITA INSTITUTE OF MEDICAL SCIENCES AND RESEARCH CENTRE  
Mata Amritanandamayi Marg Sector 88, Faridabad 121002 Haryana

MRD No:136723

Page 1 of 2

Name:HEZAL SONI

Printed On:24/08/2024 17:04:21

Printed At:

### **Semilunar Valves**

Normal tricuspid aortic valve  
Normal pulmonary valve

### **Great Vessels**

Normal pulmonary artery branches  
Normal size aorta

### **Function**

Normal right ventricular systolic and diastolic function  
Normal left ventricular systolic and diastolic function

### **Inflow Haemodynamics**

Normal tricuspid valve velocity.  
Trace TR  
Normal mitral valve velocity.  
No MR

### **Outflow Haemodynamics**

Normal pulmonic valve velocity.  
No PR  
Normal aortic valve velocity.  
No AR

### **Shunts**

Left to right atrial shunt.  
No ventricular shunt.  
No patent ductus arteriosus detected

### **M Mode/2D Measurements and Calculation**

LVIDd = 2.2 cm ( z score +0.1 )  
LVIDs = 1.5 cm ( z score +0.9 )  
LA = 1.7 cm ( z score+1.6)

**Created Date:** 05/08/2024

**Created Time:** 17:53



**Signed By:** Dr. Ankit Garg  
Assistant Professor  
HN-22046  
**Signed On:** 05-08-2024 17:54



# Shah Satnam Ji Speciality Hospitals, Sirsa

NEAR SHAH SATNAM JI DHAM, DERA SACHA SAUDA,

BHADRA ROAD, SIRSA (HRY.) 125055

CONTACT No. : 01666-260222, 238659, M : 82228-64448

SHAH SATNAM JI  
SPECIALITY HOSPITALS

Patient's Name : HEZAL D/O SANJEEV

Receipt Date : 31-Jul-2024 11:18 AM

Age : 7 Month Sex: F UHID : 593520 Lab No : LB0724-18638

Sample Collected : 31-Jul-2024 11:19 AM

Referred By : SELF (L)

Reported on : 31-Jul-2024 3:47 PM

| Investigation               | Result   | Unit             | Ref. Range     |
|-----------------------------|----------|------------------|----------------|
| <b>COMPLETE BLOOD COUNT</b> |          |                  |                |
| Hb                          | 11.7     | %                | ( 13 - 17 )    |
| TLC                         | 9.500    | Cmm              | (4000-11000)   |
| <b>DLC</b>                  |          |                  |                |
| NEUTROPHILS                 | 30       |                  |                |
| LYMPHOCYTES                 | 63       |                  |                |
| EOSINOPHILS                 | 02       | %                | ( 1 - 5 )      |
| MONOCYTES                   | 05       |                  |                |
| BASOPHILS                   | 00       | Unit             | ( 0 - 1 )      |
| HCT (PCV)                   | 36.8     | %                | ( 42 - 52 )    |
| TPLC/ PLATELET COUNT        | 4.79     | Lac/Cumm         | (0.5-5.0)      |
| MCV                         | 83.4     | fL               | (78-94)        |
| MCH                         | 26.6     | pg/mL            | (27-32)        |
| MCHC                        | 31.9     | g/dL             | (32 - 38 )     |
| RBC COUNT                   | 4.41     | million/ $\mu$ l | ( 4.2 - 5.4 )  |
| <b>N RBC</b>                |          |                  |                |
| MPV                         | 7.4      | fL               | (7.5 -11.5 )   |
| RDW - CV                    | 12.5     | %                | (11.5 -14.5 )  |
| <b>PANEL (SEROLOGY)</b>     |          |                  |                |
| HIV                         | Negative | Unit             | Tri-dot Method |
| HCV                         | Negative | Unit             | Tri-dot Method |
| HBsAg                       | Negative | Unit             | (Card Method)  |

\*\*\* End of Report \*\*\*

ANILKUMAR

Printed By

Checked By  
Lab Manager

Dr. Ira Kaur Sran  
(MD Pathology)

Dr. Neha Gupta  
(MD Microbiology)



SHAH SATNAM JI  
SPECIALITY HOSPITALS

# शाह सतनाम जी स्पैशलिटी हॉस्पिटल्स

भादरा रोड़, शाह सतनाम जी धाम, सिरसा ( हरियाणा ) 125055

## CEMRI BRAIN

|              |                           |         |          |
|--------------|---------------------------|---------|----------|
| Patient Name | : HEZAL do SANJEEV        | UHID    | : 593520 |
| Exam Date    | : Thursday, July 18, 2024 | Age/Sex | : 06M/F  |
| Referred By  | : Dr.                     |         |          |

### Findings: -

- Cystic fluid filled cavity with internal septation is seen in the bilateral fronto-temporo-parietal and occipital lobes (L>R), left thalamus and bilateral basal ganglia showing possible communication with bilateral lateral ventricles - likely porencephaly with few of cavities areas of restricted diffusion with peripheral enhancement. Internal areas of blooming are seen. Bilateral lateral and third ventricles are compressed. Midline shift of approx. 8mm seen on right side. Areas of blooming are seen in the bilateral lateral, third and 4th ventricles - likely due to previous hemorrhage. Left descending transtentorial and uncal herniation is seen
- Leptomeningeal enhancement seen in bilateral cerebral parenchyma s/o meningitis. No significant ependymal enhancement seen at present.
- The posterior fossa structures appear grossly normal.

### Advised clinical and CSF study correlation

Dr. DINESH KUMAR  
MBBS,MD (Radiodiagnosis)  
Consultant Radiologist  
Regn.HN. 6483

  
Dr. SANDEEP KAUR  
MBBS DNB  
Consultant Radiologist  
Regn.HN. 21676

Dr. KRISHAN KUMAR  
MBBS DNB  
Consultant Radiologist  
Regn.HN. 21673

*Disclaimer:-The science of radiology is based upon interpretation of shadows of normal and abnormal tissue. This is neither complete nor accurate. Hence, findings should always be interpreted in to the light of clinico-pathological correlation. This is a professional opinion, not a diagnosis. Not meant for medico legal purpose*

\*Not valid for Medico Legal Purpose

[www.ssjs.com](http://www.ssjs.com)

Helpline No. 01666-260223



AMRITA INSTITUTE OF MEDICAL SCIENCES & RESEARCH CENTRE  
PAN NO: AAATM2403M , Appointment call: 01292851234  
Mata Amritanandamayi Marg, Sector 88, Faridabad, Haryana 121002

**CLINICAL LABS TEST REPORT**  
**Transfusion Medicine and Blood Centre**

|                            |                                      |                     |
|----------------------------|--------------------------------------|---------------------|
| MRD NO : 136723            | Age/Gender : 1Y/F                    | DOB : 29/12/2023    |
| Name : HEZAL SONI          | Visit Type : IP                      | Visit Code : IP0001 |
| Consultant : Anurag Sharma | Speciality : Paediatric Neurosurgery |                     |

| Test   | Result | Unit                            | Reference Range | Status |
|--|--------|---------------------------------|-----------------|--------|
| <b>Ordered Date &amp; Time :</b> 01/08/2024 19:14  |        | <b>Sample ID :</b> 0021TR240801 |                 |        |
| <b>Sample Collected D &amp; T :</b> 01/08/2024 19:16 <b>Sample Recd. D &amp; T :</b> 01/08/2024 19:27 <b>Result Certified D &amp; T :</b> 01/08/2024 19:55 |        |                                 |                 |        |

**Blood Grouping and Rh Typing** O Positive RC  
Method: Column Agglutination Technology (CAT)  
Specimen Type: Plasma

-----  
\*\*\*\*\*End Of Report \*\*\*\*\*

Dr. Rahul Katharia

MCI REG NO : 50560

PR- Provisional Report, RC- Result Certified, RR- Result Rectified

D - Date, T - Time

L - Low, H - High, CL - Critically Low, CH - Critically High

**CLINICAL LABS TEST REPORT**

**Hematology**

|                                       |   |                            |
|---------------------------------------|---|----------------------------|
| <b>MRD NO : 136723</b>                | <b>Age/Gender : 1Y/F</b>                    | <b>DOB : 29/12/2023</b>    |
| <b>Name : HEZAL SONI</b>              | <b>Visit Type : IP</b>                      | <b>Visit Code : IP0001</b> |
| <b>Consultant : Dr. Anurag Sharma</b> | <b>Speciality : Paediatric Neurosurgery</b> |                            |

| Test | Result | Unit | Reference Range | Status |
|------|--------|------|-----------------|--------|
|------|--------|------|-----------------|--------|

**Ordered Date & Time :** 01/08/2024 19:14 **Sample ID :** 0219HA240801

**Panel :** Prothrombin Time with INR [Panel]

**Sample Collected D & T :** 01/08/2024 19:16 **Sample Recd. D & T :** 01/08/2024 19:22 **Result Certified D & T :** 02/08/2024 10:39

|  |      |     |              |    |
|--|------|-----|--------------|----|
| <b>Prothrombin Time</b><br>Method- Coagulometric (Turbidimetric) measurement<br>Sample type - Citrate plasma | 10.8 | sec | 10.1 to 12.7 | RC |
| <b>INR</b><br>Method - Calculated  | 0.96 | sec | 0.88 to 1.11 | RC |
| <b>MNPT</b>  | 11.3 | sec |              | RC |

\*\*\*\*\*End Of Report\*\*\*\*\*



Dr Ruchi Gupta  
MD PATHOLOGY

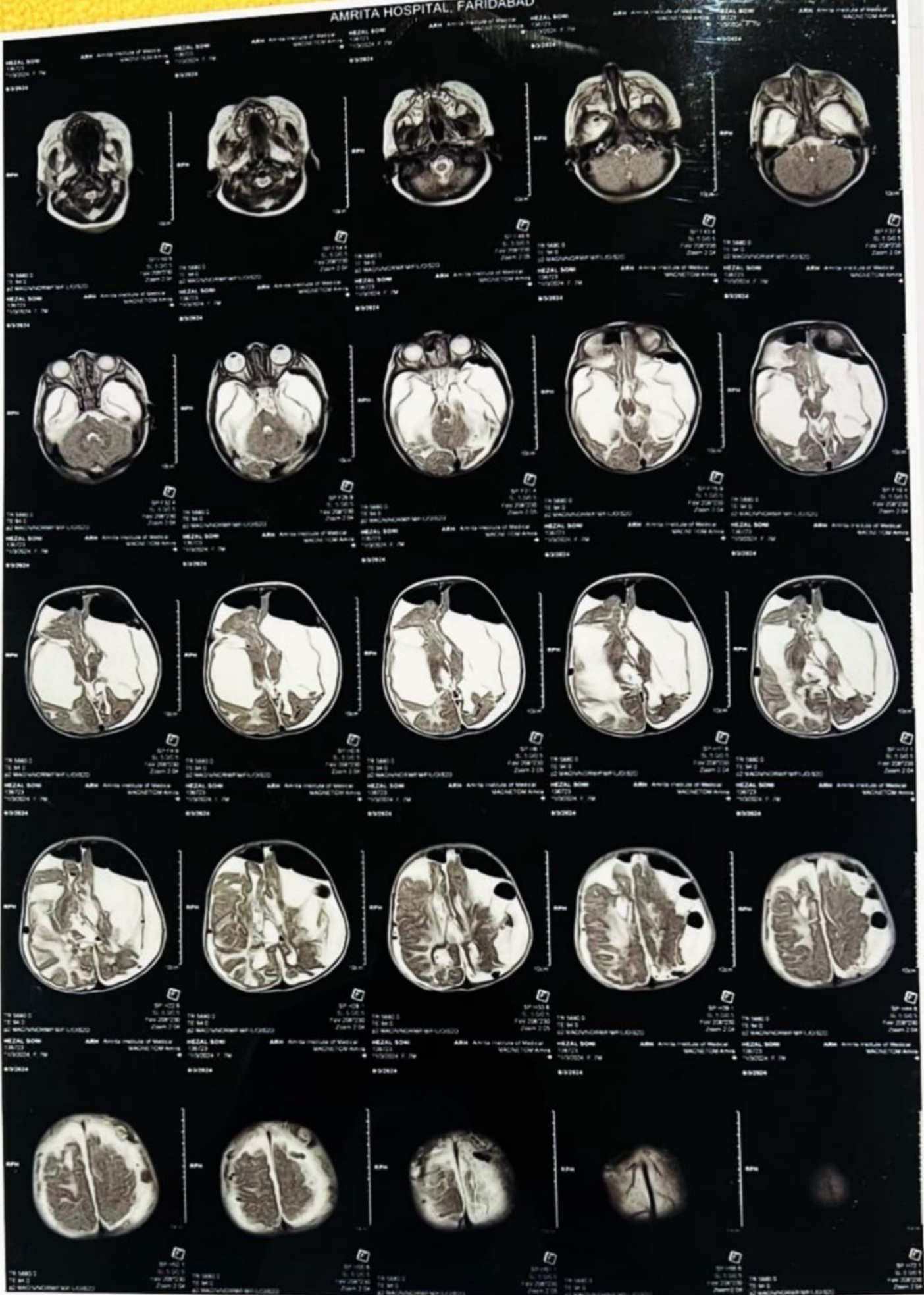
DMC/R/18125

PR- Provisional Report, RC- Result Certified, RR- Result Rectified

D - Date, T - Time

L - Low, H - High, CL - Critically Low, CH - Critically High

AMRITA HOSPITAL, FARIDABAD







Embrace Good Health

AMRITA INSTITUTE OF MEDICAL SCIENCES & RESEARCH CENTRE  
PAN NO: AAATM2403M , Appointment call: 01292851234  
Mata Amritanandamayi Marg, Sector 88, Faridabad, Haryana 121002

### In Patient Collection & Appropriation

|                  |                           |              |                    |
|------------------|---------------------------|--------------|--------------------|
| M R D Number     | : 136723                  | Patient Name | : HEZAL SONI       |
| Visit Number     | : IP0001                  | Date         | : 04/08/2024       |
| Category         | : GNL                     | D.O.A        | : 01/08/2024 15:03 |
| Admitting Doctor | : Dr. Anurag Sharma       | D.O.D        | : 04/08/2024 12:19 |
| Speciality       | : Paediatric Neurosurgery | Bed Number   | : CCU/2149         |
| Payer            | :                         | Sponsor      | :                  |

### Summary of Transactions

|  | Charges(Rs)      | Credits(Rs)      |
|--|------------------|------------------|
| Amrita Institute of Medical Science [Annexure-1] | 112446.95        | 0.00             |
| Sudhamayi Enterprises Pvt Ltd [Annexure-2]       | 47947.33         | 0.00             |
| Advance Amount [Annexure-3]                      | 0.00             | 90000.00         |
| Paid Amount                                      | 0.00             | 70394.28         |
| Refunded Amount                                  | 0.00             | 0.00             |
| <b>Total :</b>                                   | <b>160394.28</b> | <b>160394.28</b> |
| <b>Net Amount Due (Rs)</b>                       | <b>:</b>         | <b>0.00</b>      |

Total Amount Due In Words

Zero Rupees zero Paise only

Created By: Tamanna Chaprana

Prepared By: Dimple



Stamp